

RECONSTRUCTIVE

Management of Patient with Closed Degloving in the Pelvic Region: a Case Series

Tessa Miranda Atmadja, Gentur Sudjatmiko
Jakarta, Indonesia.

Background: Degloving injuries in pelvis, torso and extremities present a challenge in wound management. Current management usually is the effort to provide wound coverage with split thickness skin graft (STSG). Problems arise in the wound bed preparation because the patient is not mobile, urine or feces contamination, and systemic problems such as anemia, hypoalbuminemia and sepsis. After wound coverage with STSG, problems arise during postoperative period caused by difficulty to maintain immobilization of the graft due to the location.

Patients and Methods: In January to February 2012, 3 patients were admitted to Cipto Mangunkusumo hospital with degloving in the pelvic region. They were treated with delayed STSG.

Results : The first patient underwent delayed STSG with a 75% take. The second patient was treated by serial STSG a month following hospital admission, the result was almost 90% take. The last patient underwent debridement and the wound was closed with STSG 10 days after admission, the result was only 50% take.

Summary : Management of degloving patients should include adequate wound bed preparation with dressing that minimize infection and enhance good granulation tissue, maintain good systemic condition by providing adequate nutrition with care to albumin and electrolyte loss. Care should be given to prevent SIRS and sepsis. After wound coverage with STSG, modalities to immobilize the graft and maintain ideal environment for graft take have to be considered.

Keywords : pelvic degloving, STSG

Latar Belakang : Trauma *degloving* pada pelvis, torso dan ekstremitas merupakan tantangan penanganan luka. Tata laksana saat ini ditujukan untuk menutup luka dengan *split thickness skin graft* (STSG). Masalah muncul dalam preparasi *bed* luka karena pasien tidak *mobile*, kontaminasi urine atau feses, dan permasalahan sistemik seperti anemia, hypoalbuminemia dan sepsis. Selama perawatan pasca penutupan defek dengan STSG, muncul kesulitan mempertahankan imobilisasi graft karena lokasi luka tersebut.

Pasien dan metode : Di bulan Januari-Februari 2012, terdapat 3 pasien dengan *degloving* regio pelvis masuk perawatan di Rumah Sakit Cipto Mangunkusumo. Ketiga pasien tersebut ditata laksana dengan STSG tertunda.

Hasil : Pasien pertama menjalani operasi STSG tertunda dengan hasil *take* 75%. Pasien kedua dilakukan STSG serial setelah perawatan satu bulan, dengan hasil *take* hampir 90%. Pasien terakhir menjalani debridement dan penutupan luka dengan STSG setelah perawatan 10 hari, dengan hasil *take* 50%.

Ringkasan : Tata laksana pasien *degloving* harus mencakup preparasi *bed* luka yang adekuat dengan balutan yang meminimalisasi infeksi dan merangsang jaringan granulasi, mempertahankan kondisi sistemik yang baik dengan memberikan nutrisi adekuat, memperhatikan kadar albumin dan elektrolit, mencegah SIRS dan sepsis. Setelah penutupan luka dengan STSG, harus diperhatikan cara imobilisasi graft dan mempertahankan lingkungan ideal demi keberhasilan graft.

Kata Kunci : *degloving pelvis*, STSG

Degloving injury is one of the most common problems associated with road accidents, especially "run-over" accidents. Areas most commonly involved in degloving injuries are lower extremity and

torso and it is associated with a high morbidity and mortality. The mechanism that causes degloving injury is "shearing force".

Slack (1952) described it as the avulsion of skin and subcutaneous tissue from the deep

From The Division of Plastic Reconstructive and Aesthetic Surgery, University of Indonesia, Cipto Mangunkusumo Hospital, Jakarta, Indonesia
Presented in 16th IAPS Scientific Meetings In Sibolangit, North Sumatra, Indonesia

Disclosure: The authors have no financial interest to declare in relation to the content of this article.

fascia with rupture of the perforating musculocutaneous vessels. The skin may remain intact as a "closed degloving" or produce an open wound known as "open degloving". In closed degloving, the skin and subcutaneous tissue is separated from the underlying fascia, creating a cavity filled with hematoma and probably liquefied fat tissue. Diagnosis of closed degloving is based on physical examination, with a soft fluctuant area as the hallmark physical finding, other signs include tire marks and friction burns. Certain diagnosis may be difficult as the soft fluctuant area may not readily appear, but gradually becomes apparent in several days.^{1,2,3,4}

The mechanism that produces degloving is as follows, when the wheel is turning, the road and the wheel produce a force that acts in the same direction, it may leave the skin intact or give a rupture on the opposite side. If the wheel runs over the limb, associated fracture of crushed injury usually occurs. When the wheel is locked, the force acts in opposing direction, producing a twisting force on the skin and friction burn is more likely. Illustration can be seen in figure 1.¹

Management of degloving injuries has evolved over time. Originally re-suturing and "wait and see" were done to observe tissue vitality. Later management includes excision of the avulsed skin and using it as full thickness graft, others proposed debridement followed with delayed skin grafting (within 1 week) or immediate skin grafting. Skin grafting can be performed with the avulsed skin as donor or fresh donor grafts.

A study was performed by McGrouther and Sully (1980) that involved 46 patients with 54 degloved limbs, treated with surgical intervention within 24 hours for 43 patients and delayed surgical treatment for 3 patients. The study showed that average hospital stay for each patient was 10 weeks, with an average of 3 operations for those treated with split skin graft and 4 operations for full thickness graft. Delayed or immediate graft showed no significant difference, although some studies showed that fresh wound is a good bed for receiving donor. There were no differences in functional aspects, only those with childhood

circumferential degloving had gait problems. Sensibility was poor in all types of cover. Cosmetic result was affected with uneven contour, quality of skin graft and location of defect. Full thickness grafts usually produce a better cosmetic result.^{1,2}

A specific type of closed degloving injury is the Morel-Lavallee lesion, described in the mid 19th century as degloving injuries occurring over the region of the greater trochanter. Treatment of this type of closed degloving injuries without fractures as recommended by Hudson, et al were hematoma evacuation, irrigation followed with placement of drain. Open debridement should be performed when there is evident contour deformity. A study in California showed that preferable approach is open debridement during surgery done for pelvis or acetabular fracture, with delayed closure post-operatively. Primary closure was reported unsatisfactory, with re-accumulation of hematoma, wound breakdown and infection. Nogueira, et al suggested debridement in the emergency setting, followed by defatting and preservation of the avulsed skin, open management of the wound until wound bed is clean, with good granulation tissue, and when patient's condition is stable the prepared graft is applied. In this report, FTSG was preserved using cryoprecipitate and graft was used 12 days after the accident. Tseng reported that Morel-Lavallee lesion can be treated using early percutaneous drainage, followed by irrigation using plastic brush and suction drainage. Immediate treatment using this technique gives satisfactory result without skin necrosis. This study also imply that in purely closed degloving, bacteria that causes infection came from circulating bacteria, which may need several days to cause infection. Another study in Turkey suggested similar debridement with the use of synthetic glue (Glubran 2) to adhere the avulsed skin after all necrotic fat and hematoma had been removed.^{3, 4, 5, 6, 7, 8}

PATIENT AND METHODS

Case 1

An 18- year-old female, with degloving in the right thigh region, associated with MT-B3

pelvic fracture. Upon admission, there was a large hematoma in the right leg, as seen in Figure 2a. Patient had a history of being run over by a truck and the mechanism included shearing injury. Operation was delayed to assess demarcation of the necrotic skin. First debridement was performed 4 days after hospital admission.

During the prolonged hospital stay, patient suffered from systemic problems. The large wound was also contaminated by faeces. Diversion of feces using colostomy was considered unnecessary. Nutritional requirement was given via oral route. Patient was given high calories and protein diet but still in malnourished condition. Defect closure was delayed due to systemic problems. Correction of systemic condition was performed with recurrent relapse.

Meanwhile, inpatient management of the patient included wound treatment using honey to reduce risk of infection, odor control and promoting good granulation tissue. Bacterial culture from the wound revealed *Pseudomonas sp.* Preparation of the wound bed was continued using honey. Sixteen days after the accident, the wound was closed with Split Thickness Skin Graft (STSG) (Figure 2b).

STSG was first evaluated 5 days post operatively, revealed 85% take. Wound care was continued using *tulle gras* dressing, gauze and elastic bandage. Patient was ambulatory 14 days post STSG. Partial failure of STSG was due to difficulty for patient positioning during inpatient treatment, inadequate elevation of the leg due to pain, and the patient was unable to fecal contamination which was inevitable.

Case 2

A 34-year-old male with closed degloving in the left inguinal and open degloving in bilateral gluteus associated with stable pelvic fracture, bladder and urethral ruptures 3 weeks before hospital admission. Mechanism of injury was motorcycle accident followed by "run-over" accident (Figure 3a). The patient underwent serial debridement and wound treatment with topical application of honey. Immediate STSG was not performed because of the presence of necrotic tissue and

exudative wound. A month after hospital admission, STSG was performed in two stages. The first STSG with left thigh as donor site, was placed on the left inguinal and gluteal. After the operation, patient was positioned in right lateral decubitus, to prevent excessive force on the STSG.

The postoperative dressing was exudative, therefore early dressing change was necessary. The first dressing change was performed on the third day after operation, without replacing the *tulle gras* dressings which covered the STSG. The STSG had a 100% take and the next dressing change was on the 8th day. Condition of STSG was good, with minimal exudate. One month after the first STSG, second STSG was harvested from the same donor site to close the defect in the right side. The STSG had a 90% take, with remaining raw surface in the gluteal and flank area. (Figure 3b) Wound dressing was continued using MEBO. Patient was then considered ambulatory and further dressing changes performed at outpatient clinic.

Case 3

A 49-year-old female with closed degloving in flank area. She was "run-over" by a truck. When the patient first admitted to the ER, demarcation of the degloved skin was not clear. Patient was debrided 1 week after the accident. (Figure 4a) Operation was delayed because patient had transient shock, followed by unstable vital signs.

Debridement revealed a large area of degloving with vast amount of necrotic tissue. Non-vital tissues were excised and the wound underwent delayed closure. Wound bed preparation for STSG was done using honey. The wound bed consisted of muscle and granulation tissue. Eight days after treatment with topical honey, wound bed showed good granulation tissue, less slough and exudate as showed in Figure 4b. Patient was trained to lay down in a prone position to prepare for STSG. Nutritional requirements were met from oral route complemented with intravenous supplementation as patient had very low albumin level and a high risk of sepsis. Antibiotic and analgesics were administered



intravenously. The patient shows gradual improvement in systemic condition.

Dressing change was performed on the third day after operation, revealed 85% take of the graft. Further changes were made approximately every 3-5 days depend on the condition of the gauze. Amount of exudate soaked gauze is an indicator for immediate dressing change. Unfortunately, at 20 days after grafting, the graft only has a 50% take. Difficulty in inpatient management involved inability of the patient to maintain lay down in a prone position for all times, inadequate nutrition lead to metabolic disturbance, and

contamination of the wound from urine and feces.

RESULT

When the first patient was discharged from our center, there was 75% STSG take. Graft failure was caused by inability to maintain leg elevation, and the graft were in contact with the bed surface. In the second patient, STSG was performed almost a month after accident, with satisfactory result of graft due to adequate wound bed preparation and ability of the patient to maintain positioning

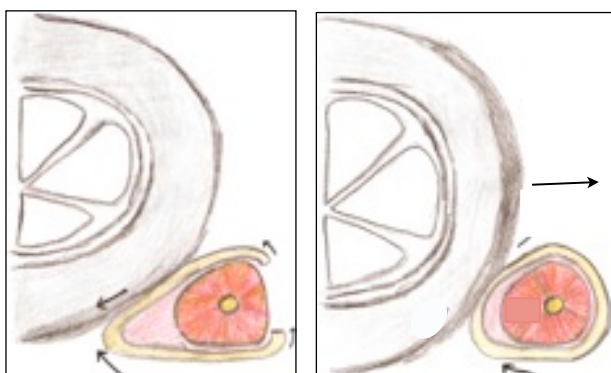


Figure 1. Mechanism of degloving. Turning wheel produce crush fractures (left). Locked wheel produces friction burn (right)

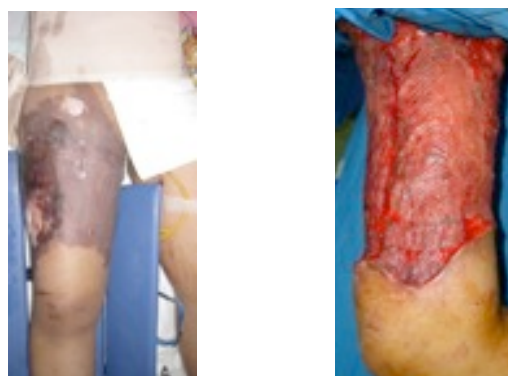

Figure 2. Case 1 **a.** Initial condition showed necrotic skin. (left) **b.** STSG seen right after operation Lateral side. (right)

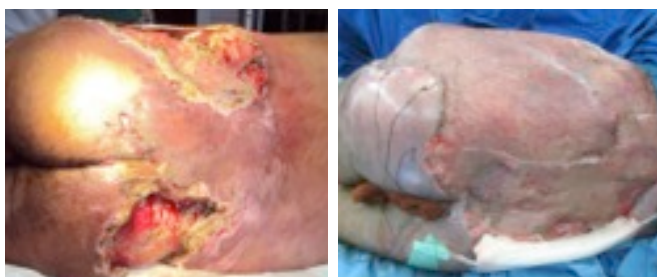

Figure 3. Case 2. **a.** First STSG were performed on the left flank and gluteal. Several stages of STSG were performed due to difficulty in patient positioning. (left) **b.** The patient's condition before surgery showed large degloving in the pelvic area with necrotic tissue and exudation. (right)

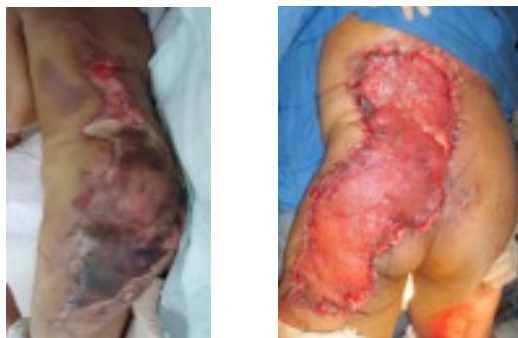

Figure 4. Case 3. **a.** Condition of the posterior trunk, 1 week after accident, showed necrotic tissue and hematoma. (left) **b.** Insetting of STSG to the gluteal and posterior trunk wound. Showing wound bed after coverage. (right)

after STSG. The third patient has only 50% take of graft due to inability to maintain prone position and unstable systemic condition.

DISCUSSION

Management of degloving injury involves several important aspects. The first aspect is management in acute settings. In the emergency setting, resuscitation includes tetanus prophylaxis and management of associated injury, such as abdominal or bladder trauma and fractures. The main problem encountered in patients with vast degloving is large denuded area which needs skin coverage. Metabolic changes due to large raw surface also occurs as a complication of degloving such as albumin loss, increased metabolism and risk of infection.^{1,3}

After management of underlying diseases, definitive treatment of the degloving injuries should be done. In open degloving, debridement of the necrotic tissue and non-vital underlying muscle must be performed. Afterwards, the demarcation of the flap was determined. The simplest way to assess extend of skin flap is to place the operator's hand underneath the flap. More accurate method involved tangential excision using dermatome or surgical blade until vital tissue was found.

After demarcation of the necrotic tissue was clear, the next step is adequate debridement, including removal of all necrotic tissue and hematoma. The denuded area resulting from debridement should be closed using graft either full thickness or split thickness graft. The avulsed skin should be defatted and used as STSG. Acute wound is good recipient for graft however uneven texture, risk of infection in immediate closure, and uncertainty about muscle vitality could pose a threat for graft take. The avulsed skin is the preferable donor site as to prevent further morbidity. In patients with closed degloving, other management options are available, which include drainage, removal of non-vital fat and hematoma, and suction drainage, this method also preserves the overlying skin.^{4,7}

Degloving injuries in the flank and gluteal area present complicated problems, especially in inpatient management (Table 1). Patient in this case series all underwent delayed grafting with fresh donor. During the prolonged hospital stay, the three patients were diagnosed with sepsis and malnutrition, indicated by physical examination, such as weight loss, pallor, and febrile supported with laboratory result that showed anemia, hypoalbuminemia and increased leucocytes

Table 1. Problems encountered in inpatient management before STSG

Challenges in STSG preparation

Large raw surface area which make wound management difficult

Wound bed preparation

Commonly associated with pelvic fracture, which make mobilization difficult, moreover the use of external fixation complicates the dressing change

Risk of pressure sore


Maintaining optimal systemic condition

Continuous pressure on the wound

Damp environment in the gluteal region allows bacterial growth

Contamination of the wound as the location is close to inguinal and perineum region

Psychological aspect



count. The second patient experienced electrolyte imbalance and depression during treatment and the third patient had a history of hypovolemic shock.

After definitive treatment with STSG, several problems are still encountered, which include exudative wound, unstable systemic condition and difficulty in immobilizing the graft. To increase the chance of graft take, STSG must be evaluated early and first dressing change performed 2 or 3 days after operation to make sure that the wound is not exudative, with no hematoma. To immobilize the graft, it can be fixated using sutures or skin staples. Monitoring of albumin and electrolyte levels should be performed regularly and any abnormality corrected. Patient will also need assistance for daily activities and hygiene of the surrounding area should be strictly maintained.

SUMMARY

Optimal management for patient with degloving injury starts in the acute setting, with proper assessment of local and systemic condition. Debridement and assessment of skin vitality should be adequate, with good inpatient wound management to control exudate and topical treatment with honey to stimulate good granulation tissue, prevent desiccation and antibacterial effect to prevent sepsis. Proper care of graft which include immobilization and frequent dressing changes to prevent contamination. Maintain good overall condition is essential including in order to achieve good holistic outcome.

Gentur Sudjatmiko, MD

Division of Plastic Surgery

Cipto Mangunkusumo General Hospital, Jakarta

dr_gentur@yahoo.co.id

REFERENCES

1. McGrouther DA, Sully L. Degloving injuries of the limbs: long term review and management based on whole body fluorescence. *Br. J. of Plast Surg.* 1980; 33: 9-24.
2. Kudsk KA, Sheldon GF, Walton RL. Degloving injuries of the extremities and torso. *The Journal of Trauma.* 1981; 21, 10: 835-9.
3. Mandel MA. The management of lower extremity degloving injuries. *Ann Plast Surg.* 1981; 6(1): 1-5.
4. Tseng S, Tornetta III P. Percutaneous management of Morell-Lavallee lesions. *JBJS.* 2006;88-A:92-6.
5. Hak DJ, Olson SA, Matta JM. Diagnosis and management of closed internal degloving injuries associated with pelvic and acetabular fractures: The Morel-Lavallee lesion. *The Journal of Trauma: Injury, Infection, and Critical Care.* 1997; 42(6): 1046-51.
6. Hudson DA, Knottenbelt JD, Krige JEJ. Closed degloving injuries: results following conservative surgery. *Plast Reconstr Surg.* 1992;89:853-5.
7. Nogueira A, et al. Delayed full-thickness autografting of cryopreserved avulsed skin in degloving injuries of the extremities. *Plast Reconstr Surg.* 2001;07(4):1009-13.
8. Demirel M, et al. Morel-Lavallee lesion. Result of surgical drainage with the use of synthetic glue. *Saudi Med J.* 2007; 28(1): 65-67.