

RECONSTRUCTIVE

Curettage and Policresulen Tampon as A Modality Treatment in Management of Verucca

Huntal Simamora, Puri Ambar Lestari, Kristaninta Bangun, Gentur Sudjtmiko
Jakarta, Indonesia.

Background: Verruca, also known as warts is a skin disease characterized by epidermal growth. Verruca may occur anywhere especially on palms and soles. It appears as a rough, dark-grey colored surface and has similar features with clavus or callus, which frequently lead to inappropriate management.

Patient and Method : We report two cases with verruca, one was on sole and another was on palm area treated with curettage and chemical ablation using policresulen solution. Both cases have histories of recurrences from the previous treatment, which was excision and primary closure.

Results : The wound healed within seven days after treatment. There were no recurrences found after 6-month follow up.

Summary : Our treatment (curettage and chemical ablation using policresulen) has two advantages: (1) it can avoid excessive tissue removal since this lesion only affect epidermal layer,

Pendahuluan: Veruka atau warts adalah kelainan kulit dengan pertumbuhan epidermis yang dapat terjadi di semua kulit tubuh terutama pada telapak tangan dan kaki, dengan tampilan kulit permukaan kasar dan berwarna abu-abu gelap. Ciri-ciri lesi pada veruka yang menyerupai kalus atau klavus sering menyebabkan terjadinya kesalahan penanganan.

Pasien dan Metodologi: Kami melaporkan penanganan veruka pada dua kasus. Satu kasus veruka plantaris dua kali residif dan satu kasus veruka palmaris enam kali residif yang sebelumnya ditangani dengan eksisi dan jahit primer. Pada kedua kasus tersebut dilakukan kuretase dan dibakar (ablasi kimia) dengan policresulen.

Hasil: Pada evaluasi hari ke-7, didapatkan luka menyembuh dan tidak ditemukan rekurensi pada pengamatan 6 bulan.

Ringkasan : Terapi kuretase dan pembakaran/ablasi kimia memakai policresulen memiliki keuntungan yaitu, (1) mencegah kerugian akibat eksisi yakni terbuangnya jaringan dermis dan sekitarnya karena lesi hanya di epidermis saja, dan (2) mengurangi resiko residif akibat penyebaran virus jika dilakukan eksisi.

Verruca, also known as warts is a skin disease characterized by epidermal growth. It appears as a rough, dark-grey colored surface and has similar features with clavus or callus, which frequently lead to inappropriate management. Commonly, verruca manifests as slow growth lesion with proliferation in the skin and mucous layer due to viral infection.^{1,2}

Verruca is a skin disease that has been reported since the ancient Greece and Rome. The disease can reduce patient's quality of life due to embarrassment resulting from negative judgment of

others. In addition, it is difficult to overcome verruca and it tends to recur.³ Onset of verruca is at pubertal age and young adulthood. Generally encounter at school age as children begin to share contact with other people and contaminated object. The lesion mainly located in moist areas of the body, because moist environment supports the growth and spread of the lesions. The frequent predilection areas are soles and palms, which are moist due to the occurrence of many sweat glands.²

The aim of this report is to reaffirm verruca management simply by curettage and

From The Division of Plastic Reconstructive and Aesthetic Surgery, University of Indonesia, Cipto Mangunkusumo Hospital, Jakarta, Indonesia

Disclosure: The authors have no financial interest to declare in relation to



PATIENT AND METHODS

Case 1

chemical ablation provides good aesthetic result and reduces the potential to recur due to seeding during the surgery.

A 12-year-old girl came to the outpatient department complaining of lumps on her right sole and tenderness when walking, thus disturbed her daily activities. The condition of the hands and feet were sweaty and moist, with a lack of self hygiene out of the habit changing socks once a week and a high mobility according to the age. Physical examination showed multiple hyperpigmented papules with hyperkeratosis at the right plantar since four years ago. Originally it was only a single lesion in the fourth plantar metatarsal and had been excised followed by primary closure. Within a month, lesions recurred with occurrence of new lesions in surrounding areas (Figure 1).

It was decided to perform curettage followed by policresulen tampon. Under local anesthesia, an incision was made at the edge of the lesion using number 15-blade to facilitate curettage. Curettage was performed until the normal soft tissues were exposed. Bleeding was controlled, followed by tamponing the lesion using gauze soaked in policresulen which acts as thermal and chemical ablative agent. It also burns the surrounding tissue which may still contain the virus. Wound then covered with tape. Policresulen was only applied for one day postoperation to avoid the deepening of the wound (Figure 2 and 3).

Evaluation on 6th day following the surgery, the wound has experienced spontaneous epithelialization. In 4-month follow up, there was no raw surface. On the fourth metatarsal, the skin looks

Case 2

hypopigmented without pain and no visible growth of new lesions (Figure 4). Hypopigmented skin area around the wounds were possibly due to a history of

policresulen applications in a long period resulted in an obvious scar.

A 26-year-old female came to the outpatient department complaining of painless lesions on her right palm that interfere aesthetic appearance as they grew since four years ago. Examination showed hyperkeratotic hyperpigmented papular lesions on the right palm. Six surgical removals were performed by local GP by excision and primary closure, but the lesions recurred with addition of new lesions. The hands and feet of the patient were sweaty and moist (Figure 5).

It was decided to perform curettage followed by policresulen tampons. Under block anesthesia, we performed the same procedure as in the first case followed by pathological examination. Hyperkeratolytic epidermis of skin tissue, hypergranulosis,

DISCUSSION

achantotic, papilomatotic, and coilocyte (vacuolated cells) were seen, which confirmed the verruca.

Four months following the surgery, wound was closed with visible hypopigmented scar in the proximal phalanx of 3rd digit, probably due to policresulen exposure, but there were no recurrences (Figure 5).

Verruca is epidermal growth associated with Human Papilloma Virus (HPV).¹ HPV is a small size DNA virus (50–55 nm). By DNA hybridization, PCR and DNA sequences homologous examination, it is known some types of HPV. HPV types 1, 2, 4, 27, and 29 are the viruses that manifest as warts on the palms, soles, oral and genitalia mucosa. HPV type 5, 8, 9, 12, 14, 15, 17, 19–26 are the cause of epidermodysplasia verruciformis and warts in immunosuppressed patients. HPV type 6 and 11 are typical in genital warts and has the potential for malignancy.^{2, 4}

According to Fitzpatrick, verruca spreads easily, especially in open wounds. Important predisposing factor is the bare skin with laceration or maceration. This is

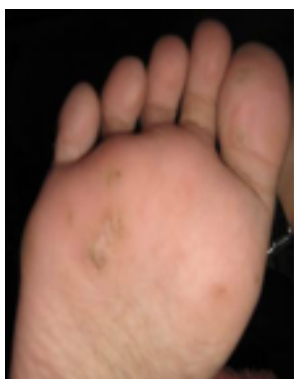

Figure 1. Multiple recurrent of verruca right plantar pedis, even after surgery.

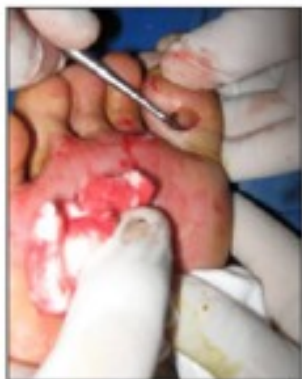

Figure 2. After incising the lesion outer edge, curettage was performed, No

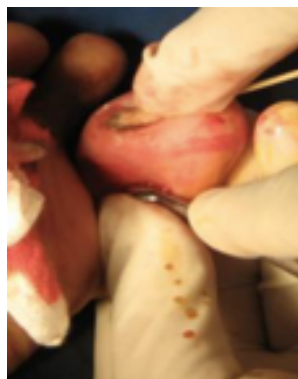


Figure 3. Putting small cotton with policresulent applied over the lesions, for haemostasis and burn remaining lesion.

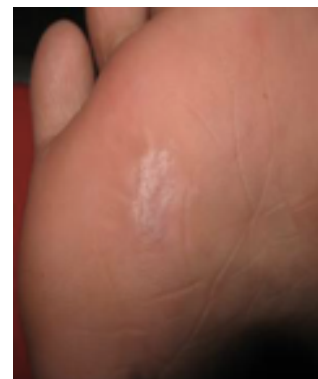

Figure 4. 4 month follow up Case 1. No

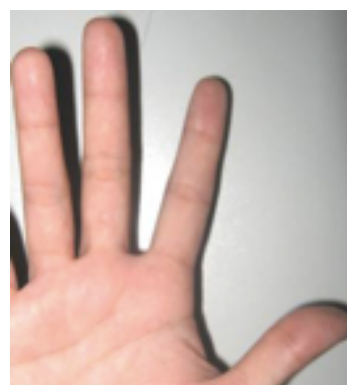

Figure 5. (Left) Hyperkeratotic hyperpigmented papular lesions on the right palm. **(Right)** Four months after polycresulent

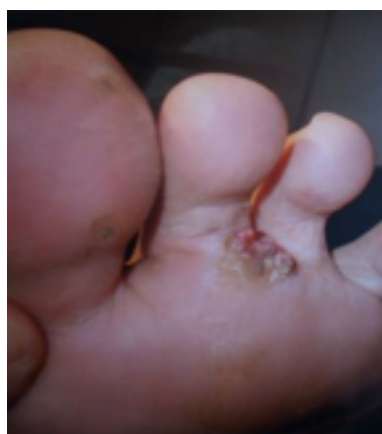

Figure 6. Note verruca lesion on 1st digit, resemble callus or clavus. Compare it with the verruca on the 2nd digit.

the cause of highest incidence in the palms and soles, which was contracted from public facilities such as swimming pools and general bathrooms. In addition, high humidity due to sweat on the palm and sole regions provides an ideal condition for the HPV.² Incubation period varies from one week to several months. The virus inoculates in the vital epidermal tissue.² Lies locally in the epidermis, surgery should be concentrated only in the epidermal layer, unless for the lesion in the plantar that covered by callus. Treatment is indicated for lesions which are painful, interfere walking process, or multiple. Chemical treatment may be used to treat verruca, such as salicylic acid 5%, formaldehyde, nitric acid, silver nitrate, podophylin, CO₂ and liquid nitrogen.^{1,2,3,5,7} Recommended surgical treatment is curettage under local anesthetic and vasoconstrictor.⁷ Incision around the lesion edge is made using scalpel, followed by curettage to totally remove the lesions. Bleeding was controlled with electrocautery, wounds were left without suturing. Within 2–3 weeks, the wound is expected to heal secondarily.^{4,7} In this case, we used policresulen for bleeding control. Policresulen, known by its brand name Albothyl®, is a chemical agent, classified as a local haemostatic. Policresulen is a polymolecular organic acid. It coagulates necrotic or pathogenically altered tissue and promotes desquamation of such tissues. The healthy tissues surrounding the wound are not affected. As a local hemostatic, Policresulen coagulates blood proteins thereby inducing muscle fibers of small vessels to contract and thus any hemorrhage could be controlled. It also induces hyperemia in the wound area and thereby stimulates regeneration and re-epithelization process. It also has an antimicrobial property which guards against infection and prevents inflammation. Policresulen also has astringent property and thus it suppresses oozing.¹²

In the second case, there is a point to be emphasized i.e. verruca's clinical

SUMMARY

manifestations often resemble callus or clavus, which lead to inappropriate management and recurrency (Figure 6). Curettage therapy and chemical ablation using policresulen have the advantages to prevent tissue losses due to excision deeper than epidermis and to reduce the risk of recurrency due to viral seeding resulted from excision.

In both cases, the skin color looks more hypopigmented after four months following the surgery. This is suspected due to prolonged exposure of policresulen or the excision reach the dermis layer. To achieve optimal results, the exposure time to policresulen and the depth of the excision should be carefully considered. The optimum duration of policresulen application to avoid hypopigmentation needs further research.

Huntal Simamora, MD

Plastic Surgery Department

Cipto Mangunkusumo Hospital, Jakarta

drhuntal@yahoo.com

We report two cases of verruca with

REFERENCES

history of recurrence, previously treated with excision and primary sutures. Histopathological examination shows papillomatous epidermal layer that requires careful attention to remove the lesion completely. On solitary and non extensive verruca, we emphasized sharp curettage technique to remove the lesion, bleeding control and chemical ablation using policresulen, and the wound was managed by ointment application several times a day. Spontaneous epithelization occurs within six days. There were no recurrency in 4-month follow up. Yet there were scar formation, possibly caused by prolonged policresulen exposure. It is suggested to use policresulen tampon in shorter period that sufficient to stop the bleeding.

1. Brunicardi FC. Principles of surgery 8th ed. McGraw-Hill. 2005; 436.
2. Fitzpatrick TB. Dermatology in general medicine: McGraw-Hill. 1999.
3. Michelle M, Lipke M, PA-C. An armamentarium