

CRANIOFACIAL

The Correction of The Auricle in Neurofibroma with Aggressive Tumor Removal Principle and Two Stages Total Ear Reconstruction

Kristaninta Bangun, Zung Chung Chen
Gweishan, Taoyuan, Taiwan

Background: Neurofibroma is a major facial hamartoma and is one of the most destructive and debilitating disease affecting the skin, muscle, mucosa, and the skeletal systems. Involvement of the ear usually increases the dimensions of the auricular skin and underlying tissues, distorts normal architecture along with auricular malpositioning, producing an ear that is abnormal in size, shape and position. The correction of the auricle in neurofibroma and benign tumors of the head and neck has been reported, but overall favorable results appear difficult to attain. We present a case of neurofibroma of the auricle in which radical resection was performed, and reconstruction was done in a two-stage surgery with satisfactory result.

Patient and Methods: A 30 years-old female presented with type-1 neurofibroma to our office, especially concerned of a large tumor growth on the right auricle. With prior experience in treating microtia cases by Nagata's method, we performed a two-stage operation on the patient. The first operation involved excising the whole auricular mass, and fabricating as well as grafting of a three-dimensional costal cartilage framework. In the second stage, the ear was elevated.

Result: Nine months after the second surgery, the result was satisfactory with good auricular definition attained, and proper elevation of the ear at the correct anatomical site. No sign of neurofibroma recurrence was found on the surrounding reconstructed auricle.

Summary: In our experience, the correction Neurofibroma of the ear by using the aggressive tumor removal principle combined with Nagata's two-stage total ear reconstruction delivered a satisfactory result.

Keywords: *Neurofibroma, Auricle, Nagata's Method*

Latar Belakang: Neurofibroma adalah manifestasi hamartoma yang umum ditemukan pada wajah dan merupakan salah satu penyakit paling destruktif dan meresahkan yang menyerang jaringan kulit, otot, mukosa, maupun tulang. Pada telinga, manifestasinya berupa peningkatan dimensi kulit dan jaringan sekitar telinga, merubah arsitektur telinga normal dan menyebabkan malposisi, sehingga telinga tampak abnormal baik dalam ukuran, bentuk, serta posisi. Rekonstruksi bentuk telinga pada neurofibroma maupun tumor jinak kepala leher lain telah dilaporkan sebelumnya, namun hasilnya belum memuaskan. Kami membawakan sebuah kasus neurofibroma pada telinga dimana radikal reseksi tumor dan rekonstruksi telinga dilakukan dalam dua tahap operasi dengan hasil yang memuaskan.

Pasien dan Metode: Wanita berusia 30 tahun dengan neurofibroma tipe 1 datang ke klinik kami dengan keluhan utama massa berukuran besar di telinga kanan. Berawal dari pengalaman menangani pasien-pasien mikrotia menggunakan teknik Nagata, kami lakukan operasi dua tahap pada pasien tersebut. Pada operasi pertama dilakukan eksisi seluruh massa aurikula, fabrikasi dan graft pada framework tiga dimensi kartilago costa. Pada tahap kedua, dilakukan elevasi telinga.

Hasil: Sembilan bulan setelah operasi kedua didapati hasil yang memuaskan. Bentuk telinga terdefinisi dengan baik, elevasi telinga tercapai pada letak anatomis yang sesuai. Tidak ditemukan tanda-tanda rekurensi neurofibroma pada telinga dan jaringan sekitarnya.

Ringkasan: Pengalaman kami menunjukkan bahwa penanganan neurofibroma pada telinga dengan menggunakan prinsip pengangkatan tumor yang agresif, dikombinasi dengan teknik operasi dua tahap Nagata, menghasilkan rekonstruksi telinga secara utuh yang memuaskan.

From Department of Plastic and Reconstructive Surgery, Chang Gung Memorial Hospital, Craniofacial Center Chang Gung University, Medical College Presented in Indonesian Association of Plastic Surgeon Annual Meeting 13th, Malang, East Java, 2009

Von Recklinghausen's Disease or Neurofibroma was first described by von Recklinghausen and Festscher in 1882.¹ Neurofibroma is a major facial hamartoma and

Disclosure: *The authors have no financial interest to declare in relation to the content of this article.*

one of the most devastating, destructive, and debilitating diseases of the skin, muscle, mucosa, and skeletal systems.^{2,3} Although benign in histologic appearance, these facial masses can be clinically malignant in their deforming and inexorable growth.^{2,4} Radical resection of the diseased tissue in von Recklinghausen's disease has been counter-indicated by majority of the surgeons who have encountered this disease^{2,5-10} and that multiple subtotal excisions over a period of years have been recommended for treatment, especially in extremely severe cases, elephantiasis neurofibromatosa.^{2,9}

Involvement of the ear usually increases the dimensions of the auricular skin and underlying tissues, distorts the normal architecture which may cause auricular malpositioning, and produces an ear that is abnormal in size, shape and position.¹⁰ The correction of the auricle in neurofibroma^{9,10} and benign tumors and conditions of the head and neck⁸ has been reported even though overall satisfactory or favorable results appear difficult to attain. The proper anatomical location and morphological features of the auricle are extremely difficult to reconstruct in both congenital and acquired defects and always possess a challenge to a reconstructive surgeon.⁹

We present a case of neurofibroma of the auricle where we performed a radical resection of the tumor and reconstruction of the auricle in two-stage surgery, the result was satisfactory.

PATIENT AND METHODS

A 30 years-old female came to our office for a case of type 1 neurofibroma presented since birth. She had a cafe-au-lait stain and multiple neurofibroma nodules covering almost all areas of her body from foot to scalp. The patient was referred especially with the concern of a large benign tumor growth over her right auricle, which was believed to be neurofibroma (Figure 1). From prior experience in treating microtia patients using Nagata's technique,¹¹ we performed a two-stage operation on the patient: the first to discard the mass on her right auricle totally, then fabricate and graft a three-

dimensional costal cartilage framework, and in the second stage the ear was elevated.

Operative Techniques

Prior to surgery, the proper anatomical shape, size and location of right auricle were adjusted according to the opposite normal auricle by a transparent film template. The template was also used to mark the long axis of the auricle to attain postoperative facial symmetry (Figure 2).

Intraoperative, the skin quality over the mass was found to be very poor, warranting a total removal of the mass (Figure 3). A zig-zag incision on the temporal area was made to raise

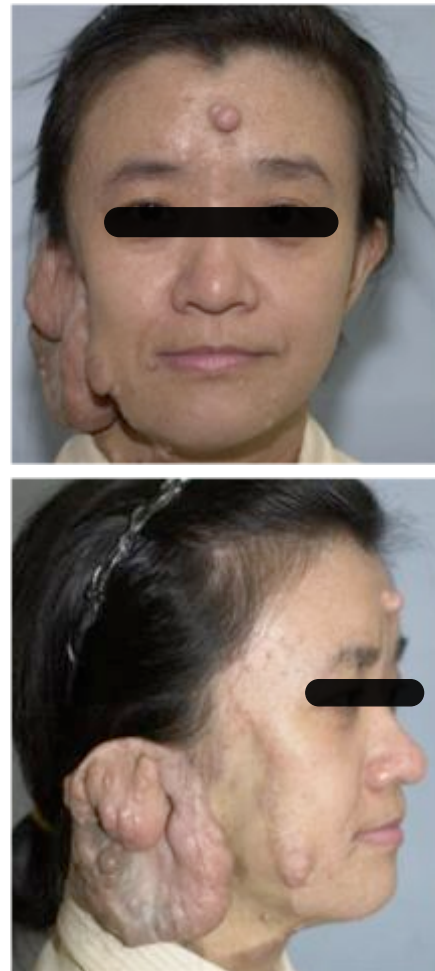

Figure 1. A 30-year-old woman with Von Recklinghausen's disease presented with a chief complain of a large mass on the right ear. (*Upper*) Frontal view, (*Lower*) Right lateral view.

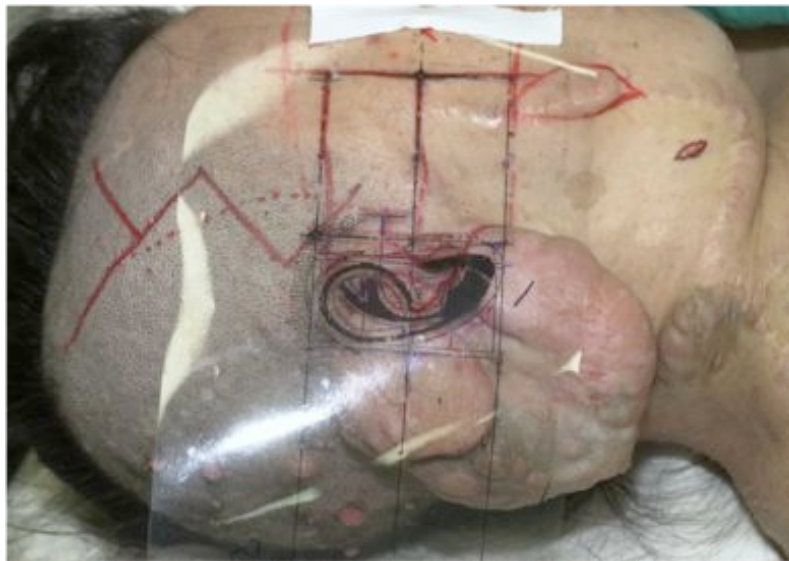

Figure 2. A transparent film template obtained from the contralateral ear is used to mark the axis, shape, size, and location of the affected auricle.

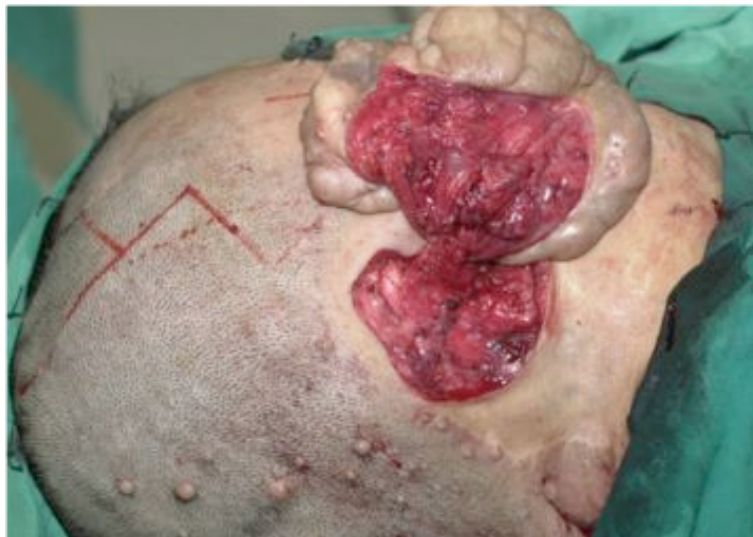

Figure 3. The skin quality of the mass was poor, the mass was removed *in toto*. The external acoustic meatus was found intact as shown in the next picture.

a 12-cm by 15-cm temporoparietal fascia (TPF) flap. The superficial temporal artery was included in the flap at the medial edge to assure flap viability, and the external acoustic meatus was found intact (Figure 4). To fabricate a three dimensional (3-D) frame, the 6th through 9th costal cartilage were harvested en bloc with the perichondrium intact through a 7-mm transverse skin incision on the ipsilateral chest. The cartilage frame was then designed according to Nagata's method for microtia reconstruction and fabricated with 4-0 a double

armed stainless steel wires (Surgical Stainless Wire Suture, Unik GMP, Medigate, Taiwan) (Figure 5).

Since there was no tragus structure remained, a lobule-type microtia 3-D framework was used in the patient. The 3-D cartilage framework was then covered with TPF flap (Figure 6). Care was taken to adapt the fascia flap to the cartilage framework definition by continuous suction. The TPF donor site was closed primarily using skin stapler. Bolster sutures with rolled gauze soaked in Neomycin

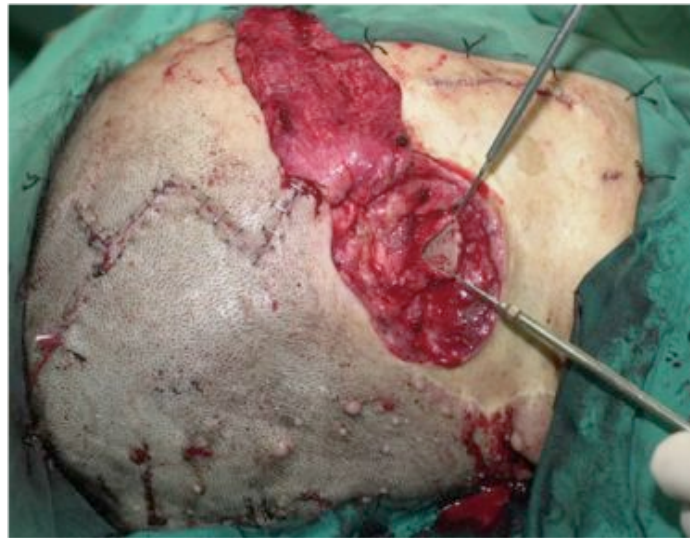


Figure 4. The temporoparietal fascia flap was raised through a zig-zag incision on the temporal area, and closed using skin stapler.

Bacitracin ointment was then applied onto the indentation and around the reconstructed auricle.

The last step in the first stage was to cover the TPF flap with a thick split-thickness skin graft harvested from a temporal hair bearing area as seen in Figure 6. Scalpel no. 15 was used to harvest the skin graft, and donor site covered with biological dressing (Allevyn Adhesive, Smith & Nephew, USA). Finally the reconstructed auricle was protected with full circled Reston sponge and gauze dressing. Postoperatively, no complication ensued. One month after the surgery, the auricular contour was still not clearly defined due to residual swelling (Figure 7, left). Six months after the first surgery, the edema had subsided and the

ear appeared in good shape with a well-defined contour at the appropriate position (Figure 7, right).

The second stage of surgery to elevate the auricle was performed six months after the first stage. Access was made through the previous temporal scar to reach the deep temporal fascia. The skin grafts donor site from prior surgery healed well with full hair growth. Skin incision was made along the helical rim, approximately 5-mm off the helical rim edge to wrap around the top of the helix. Hair-bearing skin was included in this marking, therefore intra-operative epilation was planned with the hair-bearing skin at the helical rim raised at the depth of thin skin graft. Subcutaneous tissue below the skin including hair follicles were

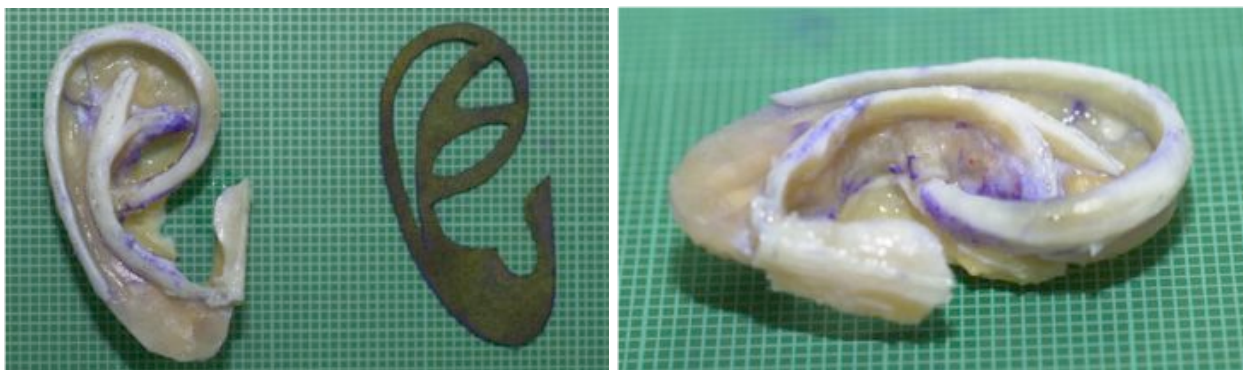


Figure 5. The cartilage frame was designed according to Nagata's method for lobule-type microtia reconstruction and fabricated with 4-0 a double armed stainless steel wires. Upper: Anterior view of framework, Lower: Lateral view of framework.

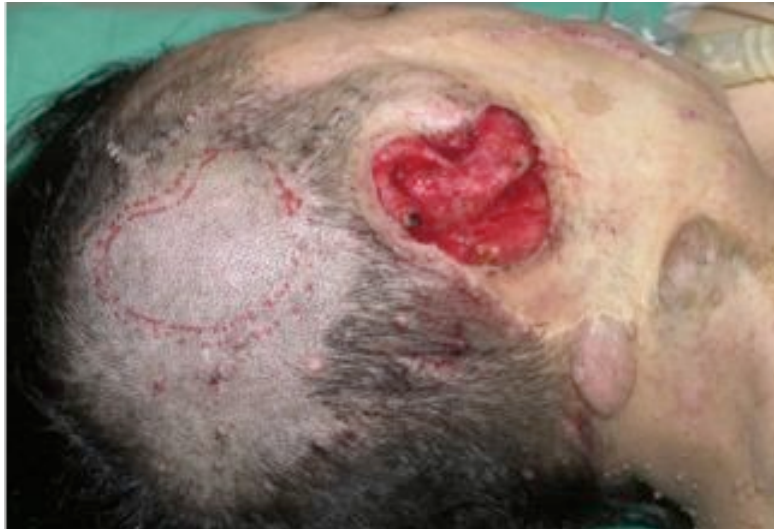

Figure 6. The cartilage frame insetted onto the defect, covered with the temporoparietal fascia flap, then closed by split thickness skin graft obtained from the temporal hair bearing area.

removed. The size of the deep TPF flap was 8-cm by 12-cm (Figure 8).

The sixth costal cartilage was harvested without perichondrium from the contralateral chest and carved into a semilunar-shaped block (Figure 9) with a 4-0 double armed stainless steel wires. The cartilage block design configuration was based on the ipsilateral fabricated antihelix and the projection of the normal contralateral ear. The semilunar costal cartilage was then fixed to the posterior surface of the constructed ear and the mastoid, covered by the deep TPF and finally skin grafted from the postauricular scalp. Nine months after the

second surgery result was found to be satisfactory, with good auricular definition, proper elevation of the auricle located in the correct anatomical site (Figure 10). No sign of neurofibroma recurrence on the area of reconstructed auricle was found.

DISCUSSION

Neurofibroma (NF) is an autosomal dominant genetic disorder which affects the nervous system by causing tumors to grow on nervous tissue throughout the body, along with a number of other individual specific

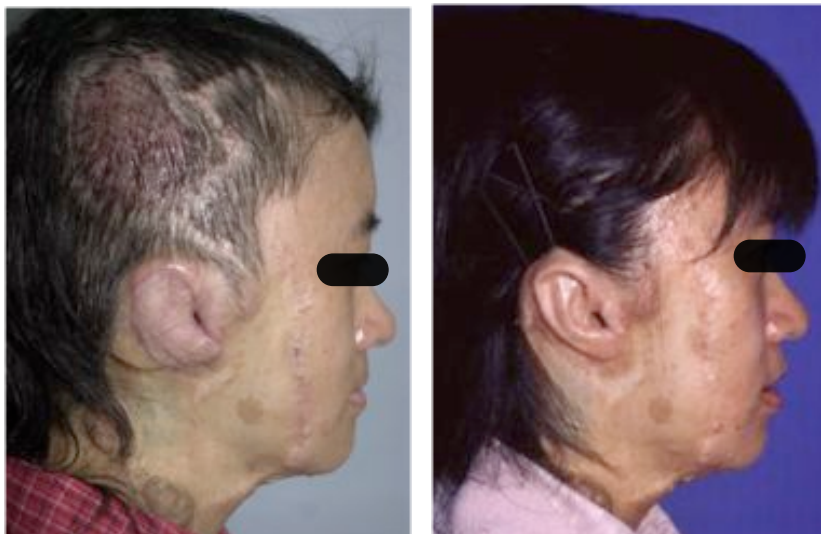

Figure 7. (Left) 1-month after stage-one surgery the auricular contour was still not clearly defined due to residual swelling. (Right) 6-months later the edema had subsided and the ear had a well-defined contour at the appropriate position.

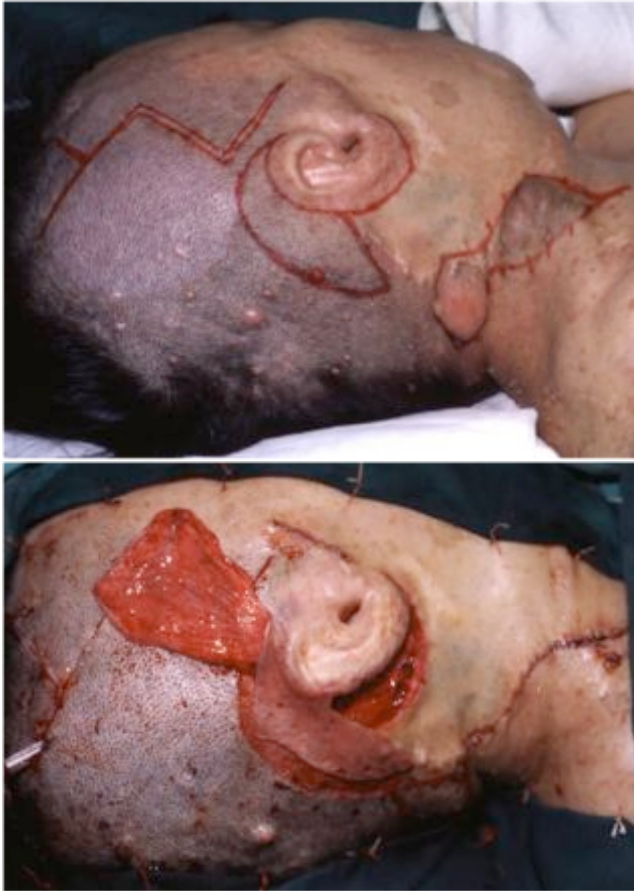


Figure 8. (Upper) Design of the second stage surgery through previous incision scar to access the deep TPF. Incision was also made along the helical rim, approximately 5-mm off the edge to wrap around helix. Hair-bearing skin was included and epilation performed. (Lower) A 8-cm by 12-cm TPF flap raised.

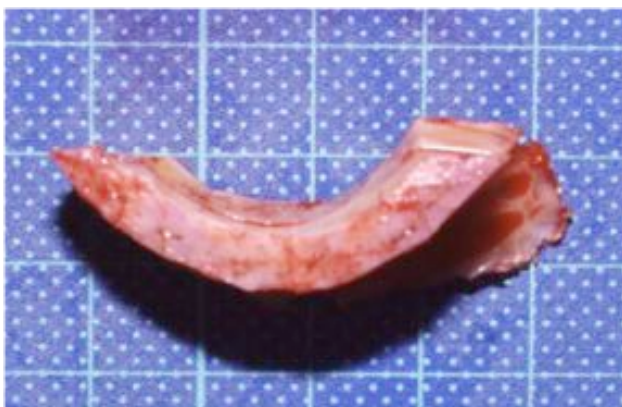

Figure 9. The 6th contralateral costal cartilage harvested without perichondrium and carved into a semilunar-shaped block with a 4-0 double armed stainless steel wires.

symptoms. Two main types of NF have been recognized: neurofibromatosis 1 (NF-1) and neurofibromatosis 2 (NF-2). NF-1 is much more prevalent in the population (90% of cases), affecting 1 in 4,000 individuals.

Onset of the disease often occurs as early as childhood, and people of all gender, race, and ethnicity are affected equally. The NF-1 gene is located on chromosome 17 and is characterized by tumor formations which usually manifest themselves within the peripheral nervous system. Other symptoms include Lisch nodules, cafe-au-lait spots, axillary freckling, numerous fibromas, multiple developmental problems, macrocephaly, optic glioma, hypertension, short stature, seizures, and distinctive osseous lesions.

The severity of each NF-1 case is impossible to predict, and a patient might exhibit all or just a small number of these symptoms.¹² NF-2, affects 1 in 40,000 individuals. The NF-2 gene is located on chromosome 22 and the disease itself is characterized by tumor formation primarily in the central nervous system. Identification of unilateral or bilateral acoustic tumors on the eighth cranial nerve has often been the most conclusive evidence of this disease. Other possible symptoms can include cataracts, cafe-au-lait spots, and numerous neurofibromas. Onset of NF-2 occurs during early teenage and adult years, and prognosis is often poorer due to its affect on the central nervous system.¹²

Histologically, NF shows diffuse proliferation of compactly arranged spindle shaped fibroblasts infiltrating the surrounding soft tissues, including the dermis, subcutaneous tissue, and blood vessels. The preexisting collagen bundles in the dermis and subcutaneous tissue forming a loose fibrous tissue separating the fibrous myxomatous dermis and skin. These changes cause soft-tissue detachment from skeletal support and are aggravated by facial gravitational forces.^{3,6,13}

Variable factors, such as the loss of elasticity or integrity of the remaining soft tissue, regrowth or recurrence of a progressive mass, loss of skeletal and soft-tissue support, and soft tissue detachment from the skeletal structure by tumor infiltration, contribute to

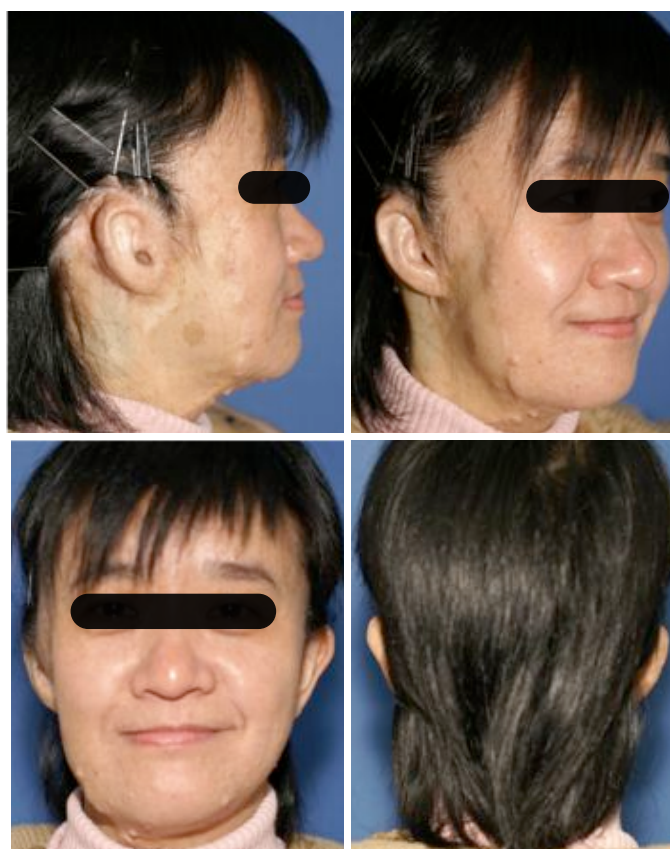

Figure 10. Final results of the right auricle, 9-months after the second stage surgery. (*Upper left*) Lateral view, (*upper right*) Oblique view, (*bottom left*) Posterior view, (*bottom right*) Frontal view.

worsen the facial deformities. Failure to intervene or to prevent such factors would result in recurrence and regrowth after resection.⁴

Our patient comes with neurofibroma type 1, with a main consideration to perform a two stage surgery to attain a better aesthetic and functional auricula. In the first stage surgery the neurofibroma tissue was removed totally, this procedure is counter-indicated by the majority of surgeons who have encountered this disease.^{2,5-10} In our case, since the margin of the tumor is well-defined on the right auricular region, neurofibroma was removed in toto. A 3D autogenous costal cartilage framework was used, with hope of a better long-term result when compared with prosthetic framework, especially in the ability to resist injury-related complications.

Brent and Byrd¹⁴ were the first to advocate the principle of aggressive excision for treating secondary ear reconstruction: remove

the entire auricular scar area, in our case it is the neurofibroma tissue, immediately placing a sculpted autogenous rib cartilage graft and covering the latter with a temporoparietal fascia flap. Nagata¹⁵⁻¹⁷ further refines Brent's principle. Yamada et al¹⁸ summarized the Nagata's principle for secondary ear reconstruction: (1) excise entire scar tissues which has no elasticity, (2) excise the anatomically abnormal ear cartilage, (3) place a precisely carved 3D cartilage framework based on normal anatomy, (4) cover the 3D frame with TPF or DTF, (5) cover the fascial flap with split thickness skin graft from scalp, (6) create conchal cavity with framework and skin flap, (7) place reconstructed ear at an anatomically correct site with the help of transparent film template.

The other problem encountered during the surgery is the lack of skin and soft tissue coverage around the framework area. Before the surgery we were sure that the tumor did not



involve the TPF, so we use a thin and pliable flap to cover the framework, and put the thick-split thickness skin graft to cover the flap. The TPF flap, first described by Edgerton and Bacchetta¹⁹, is the workhorse flap for primary reconstruction as well as secondary salvage reconstruction of the auricle.^{14,16,17,19,20} This fascial flap provides a wide surface area of tissue on a narrow-based pedicle capable of a wide arc of rotation. It provides a thin, pliable tissue which can be adapted to the needs of various reconstructive otologic or neurotologic problems.²¹ The use of a vascular pedicled temporoparietalis muscle flap resurfaced with skin graft is advocated to achieve more satisfactory aesthetic results in cases of total ear reconstruction.²²

SUMMARY

In our experience, the management and reconstruction of the ear in Neurofibroma by using aggressive tumor removal principle, combined with Nagata's two-stage total ear reconstruction technique, is successful in delivering a satisfactory auricular appearance.

Zung-Chung Chen, M.D.

Department of Plastic and Reconstructive Surgery,
Chang-Gung Memorial Hospital.

Fu-Shin Road 5. Gweishan, Taoyuan, Taiwan

Chenzc@adm.cgmh.org.tw; pczhenc2372@yahoo.com.tw

REFERENCES

1. Von Recklinghausen E, Festscher JR. Ueber die multiplen Fibroma der Haut und ihre Beziehung zu den multiplen Neuromen. Virchow's Berlin: A. Hirschwald; 1882.
2. Grabb WC, Dingman RO, O Neal RM, et al. Facial hamartomas in children: Neurofibroma, lymphangioma, and hemangioma. *Plast Reconstr Surg* 1980;66:509.
3. van der Meulen, J. Orbital neurofibromatosis. *Clin Plast Surg* 1987;14:123.
4. Park BY, Hong JP, Lee WJ. Netting Operation to Control Neurofibroma of the Face. *Plast Reconstr Surg* 2002;109:1228.
5. Marchac D. Intracranial enlargement of the orbital cavity and palpebral remodeling for orbitopalpebral neurofibromatosis. *Plast Reconstr Surg* 1984;73:534.
6. Jackson IT, Carbonnel A, Porparic Z, et al. Orbitotemporal neurofibromatosis: classification and treatment. *Plast Reconstr Surg* 1993;92:1.
7. Snyder BJ, Hanjeh A, Trott JA, David DJ. Transcranial correction of orbital neurofibromatosis. *Plast Reconstr Surg* 1998;102:633.
8. Bauer B. Benign tumors and conditions of the head and neck. In: Achauer BM, Eriksson E, editors. *Plastic surgery: indications, operations and outcomes*, vol. 3. St Louis: Mosby; 2000. p. 1129.
9. Nagata S. A systematic multiple stage surgical approach for attainment of satisfactory and favourable surgical result in an extremely severe von Recklinghausen's disease, elephantiasis neurofibromatosa. *J Plast Reconstr Aesth Surg* 2006;59:662.
10. Trevisani TP, Pohl AL, Matloub HS. Neurofibroma of the ear: Function and aesthetics. *Plast Reconstr Surg* 1982;70:217.
11. Nagata S. A New method of total reconstruction of the auricle for microtia. *Plast Reconstr Surg* 1983;92:187.
12. Wiseman J, Cullington JR, Schaeferle M, et al. Aesthetic aspects of neurofibromatosis Reconstruction with the Vacuum-Assisted Closure System. *Aesth Plast Surg* 2001;25:326.
13. Griffith BH, McKinney P, Monroe CW, et al. Von Recklinghausen's disease in children. *Plast Reconstr Surg* 1972;49:647.
14. Brent B, Byrd HS. Secondary ear reconstruction with cartilage graft covered by axial, random, and free flaps of temporoparietal fascia. *Plast Reconstr Surg* 1983;72:141.
15. Nagata S. A new method of total reconstruction of the auricle for microtia. *Plast Reconstr Surg* 1993;92:187.
16. Nagata S. Secondary reconstruction for unfavorable microtia results: utilizing the temporoparietal and innominate fascia flaps. *Plast Reconstr Surg* 1994;94:254.
17. Nagata S. Microtia: auricular reconstruction. In: VanderKolk CA, Wilkins EG, VanderKam VM, editors. *Plastic surgery indications operations and outcomes*, vol. 2. St.Louis: Mosby; 2000. p. 1023.
18. Yamada A, Imai K, Nomachi T, et al. Total reconstruction of the burned auricle. *Burns* 2007; 33:112.
19. Edgerton MT, Bacchetta CA. Principles in the use and salvage of implants in ear reconstruction. In: Tanzer RC, Edgerton MT, editors. *Symposium on reconstruction of the auricle*. 1974. p.58.
20. Wellisz T. The reconstruction of the burned external ear using a MEDPOR porous polyethylene 'pivoting helix' framework. *Plast Reconstr Surg* 1993;91:811.
21. Olson KL, Manolidis S. The pedicled superficial temporalis fascial flap: A new method for reconstruction in otologic surgery. *Head Neck Surg* 2002;126:538.
22. Nakai H, Ishii Y, Ozaki S, et al. Use of resurfaced temporoparietalis flap in total ear reconstruction with less-than-favorable skin coverage. *Aesth Plast Surg* 1984;8:253.