

Article

EFFECT OF NAM ON NASAL SYMMETRY AND PROPORTIONS IN PATIENTS WITH UCLP: A SYSTEMATIC REVIEW

Felicia Puspita Sari¹, Gede Wara Samsarga¹, Kenny Satrio¹, Theodorus Kevin Putra Johansyah¹, Jeremy Jonathan¹, & Made Dwi Andhika Yogiswara¹

1. Faculty of Medicine, Universitas Udayana, Bali, Indonesia.

Introduction : Nasal reconstruction presents a challenge in case of patients with unilateral cleft lip and palate (UCLP). Correction of the nasal deformity to achieve a symmetrical nose from the deficient columella and malformed nasal cartilage in cleft patients presents a great challenge. Nasoalveolar molding (NAM) was developed as a neoadjuvant therapy for patients with cleft lip and palate to improve nasal deformity before surgical intervention. The aim of this systematic review was to understand more about the effect of NAM on nasal symmetry and proportions in patients with UCLP.

Method : We searched for manuscripts involving patients with UCLP who received NAM prior to cleft lip repair. Electronic literature searching of the PubMed, Scopus, Cochrane and Google scholar databases was conducted for the studies that had been published up to December 2021.

Result : Presurgical NAM demonstrated benefits in nasolabial form when compared with patients who did not receive any presurgical infant orthopaedic appliances (PSIO). The use of presurgical NAM helps to achieve favourable reshaping of the nose and decrease the severity of the initial cleft deformity, resulting in improvement on nasolabial form. These changes lead to improved nasal symmetry and proportions in UCLP patients.

Conclusion: The preponderance of evidence in this review suggests that presurgical NAM is a beneficial adjuvant therapy for nasal deformity correction and helps achieve nasal symmetry in patients with UCLP. However, there is insufficient evidence to conclude whether presurgical NAM produces these benefits at the time of nasal maturity.

Keywords: *Nasoalveolar molding, NAM, Unilateral cleft lip and palate, Nasal symmetry*

Latar Belakang: Nasal reconstruction menghadirkan tantangan dalam kasus pasien dengan celah bibir dan langit-langit unilateral (UCLP). Koreksi kelainan bentuk hidung untuk mencapai hidung simetris dari columella yang kurang dan kartilago hidung yang cacat pada pasien sumbing menghadirkan tantangan besar. Nasoalveolar molding (NAM) dikembangkan sebagai terapi neoadjuvant untuk pasien dengan celah bibir dan langit-langit untuk memperbaiki deformitas hidung sebelum intervensi bedah. Tujuan dari tinjauan sistematis ini adalah untuk memahami lebih lanjut tentang efek NAM pada simetri dan proporsi hidung pada pasien dengan UCLP.

Metodologi: Kami mencari manuskrip yang melibatkan pasien dengan UCLP yang menerima NAM sebelum perbaikan bibir sumbing. Pencarian literatur elektronik dari database sarjana PubMed, Scopus, Cochrane dan Google dilakukan untuk studi yang telah dipublikasikan hingga Desember 2021.

Hasil: Prabedah NAM menunjukkan manfaat dalam bentuk nasolabial bila dibandingkan dengan pasien yang tidak menerima alat ortopedi bayi prabedah (PSIO). Penggunaan pra-bedah NAM membantu mencapai pembentukan kembali hidung yang menguntungkan dan mengurangi keparahan kelainan bentuk sumbing awal, menghasilkan perbaikan pada bentuk nasolabial. Perubahan ini menyebabkan peningkatan simetri dan proporsi hidung pada pasien UCLP.

Kesimpulan: Banyaknya bukti dalam ulasan ini menunjukkan bahwa pra-bedah NAM adalah terapi tambahan yang bermanfaat untuk koreksi kelainan bentuk hidung dan membantu mencapai kesimetrisan hidung pada pasien dengan UCLP. Namun, tidak cukup bukti untuk menyimpulkan apakah prabedah NAM menghasilkan manfaat ini pada saat maturitas hidung.

Kata Kunci: *Pencetakan nasoalveolar, NAM, celah bibir dan langit-langit unilateral, Simetri hidung*

Conflicts of Interest Statement:

The author(s) listed in this manuscript declare the absence of any conflict of interest on the subject matter or materials discussed

Received: 19-09-2022, Revised: 27-12-2022, Accepted: 31-12-2022

Copyright by Puspita Sari, et al., 2022. | P-ISSN 2089-6492; E-ISSN 2089-9734 | DOI: 10.14228/jprjournal.v9i2.341

Published by Lingkar Studi Bedah Plastik Foundation. This is an open-access article distributed under the terms of the Creative Commons Attribution-Non Commercial-No Derivatives License 4.0 (CCBY-NC-ND), where it is permissible to download and share the work provided it is properly cited. The work cannot be changed in any way or used commercially without permission from the journal. This Article can be viewed at www.jprjournal.com

INTRODUCTION

Cleft lip and palate is one of the most common congenital deformities and predisposes to distortion of facial anatomical structures. According to the statistics data, the prevalence of oral cleft is 1-2 in 1000 live births worldwide. Based on the anatomical distribution of CLP cases in terms of the affected side, data were obtained that 13% of CLP cases were bilateral, compared with 87% unilateral, with a right-to-left ratio of 1:3.^{1,2} Nasal reconstruction associated with a complete unilateral cleft lip and palate (UCLP) presents challenges to the surgeons. One of the challenges is the correction of the nasal deformity to achieve a symmetrical nose from the deficient columella and malformed nasal cartilage in cleft patients.³

The use of nasoalveolar molding (NAM) in infants with cleft lip and palate first introduced by Grayson et al.⁴ NAM is a form of presurgical infant orthopaedic appliances (PSIO) which consists of a palatal molding plate, surgical tape, and nasal stents. NAM was developed as a neoadjuvant therapy and has been used to minimize the deformity in early infancy for patients with cleft lip and palate. NAM works by repositioning deformed alveolar segments and lower lateral cartilages through active molding prior to primary cheiloplasty. The main goals of NAM therapy are to improve nasal shape and symmetry, restore the anatomic position of the alveolus, and decrease the width of the cleft.^{4,5,6}

The use of NAM has increased over the past two decades.⁶ Several studies have reported improvements in nasolabial form prior to primary surgical repair. The aim of this study was to investigate the effects of NAM on nasal symmetry and proportions in patients with UCLP.

METHOD

This study is a systematic review with comprehensive search strategies on the articles addressing the effect of nasoalveolar molding on nasal symmetry and proportions in patients with UCLP. This systematic review was performed in accordance to the Cochrane Handbook for Systematic Reviews of Interventions and to the Preferred Reporting Items for Systematic Reviews and Meta-Analyses (PRISMA)

guidelines. We created the search keyword by medical subject heading and terms relating to the target condition as follows: "nasoalveolar molding", "unilateral", "cleft lip", "cleft palate", and "nasal symmetry". We searched on PubMed, Scopus, Cochrane Library, and Google scholar for the published articles up to December 2021.

Full-text English manuscripts were eligible for inclusion in this review if they were randomized controlled trials, prospective or retrospective cohort studies, case-control studies, or cross-sectional studies. We exclude non-English papers, reviews, case reports, editorials, and studies not suitable for this systematic review. The selected papers were screened based on the eligibility criteria after a complete reading of their titles and abstracts. After that, we screened for the full text papers. The selection process of the papers is shown in the flow chart study selection (Figure 1).

The presents systematic review has been conducted in accordance with the principles outlined in the Helsinki Declaration, and all studies included in the review were conducted in accordance with these principles.

RESULTS

The search process identified 834 articles. After a detailed assessment of the full texts of the articles, 18 were selected for the final analysis (Figure 1). The resulting 18 studies consist of 1 randomized trial and 17 nonrandomized studies: 9 retrospective cohort studies, 4 prospective cohort studies, 1 prospective clinical trial study, 2 cross-sectional studies, 1 retrospective case-control study. In total, these studies involved 359 patients treated with NAM, 16 patients treated with non-NAM passive PSIO, 112 patients managed without presurgical appliances, and 10 non-cleft patients (Table 1).

Assessment Medium

Records are essential for patients to evaluate the progress and outcomes of treatment. Traditionally, photography is the most common facial recording method. Another frequently used

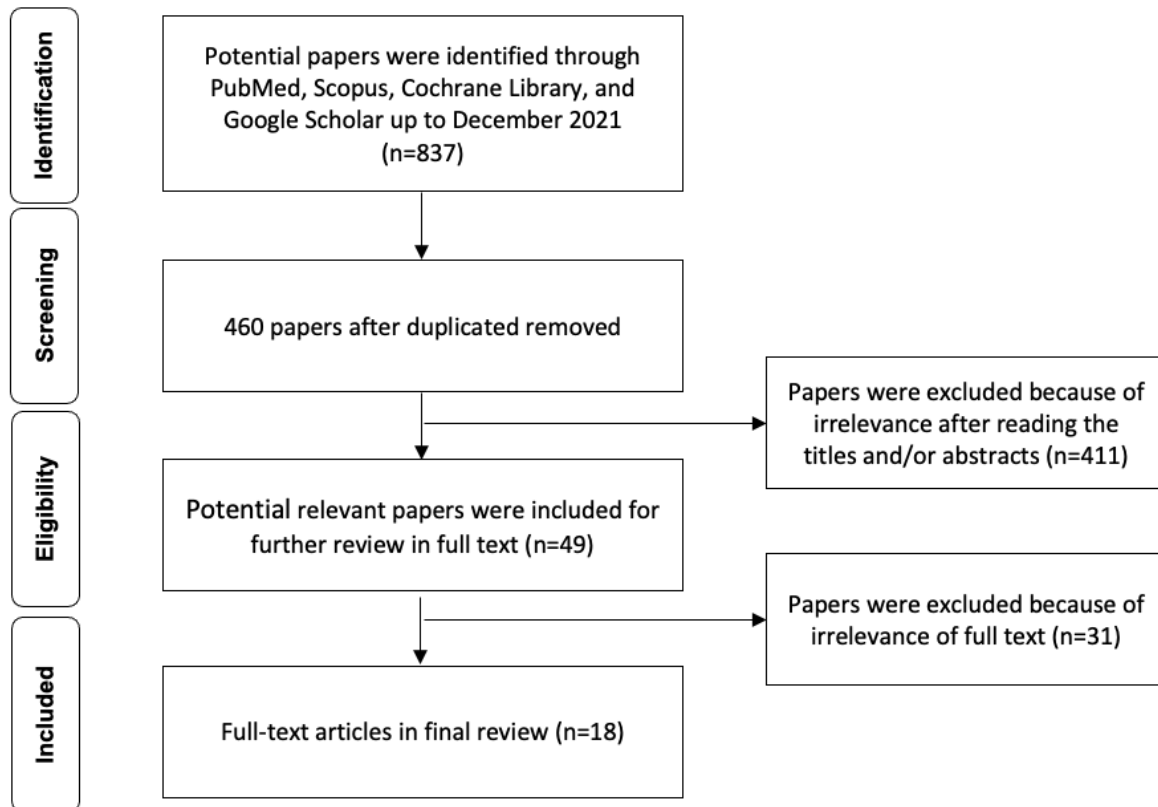


Figure 1. Flow Chart Study Selection

method is plaster model production such as nasal and maxillary casts. This method can be used to reflect the contour of nose and lips three dimensionally. Furthermore, deeper anatomical landmarks and gently curving slopes such as nostrils and alar points are not easy to measure. To overcome these disadvantages, the plaster models can be digitalized using 3D model scanner systems or imaging systems such as stereophotogrammetry were developed.^{7,8} From 18 studies included in this review, 9 studies used photographs method, 4 studies used casts methods, 2 studies used 3-D images, and 3 studies used a combination of photographs and casts methods.

Nasal parameters

Two-dimension photography is the traditional method to assess nasal symmetry by the “quantity of asymmetry”. The quantity of asymmetry (in millimetres) was the linear difference of each measurement between the cleft and non-cleft sides. These parameters can have positive and negative values. A positive value

indicates that the left side is longer or wider than the non-cleft side, and a negative value indicates otherwise. Nasal asymmetry can be observed by measuring the vertical aspects such as nostril height, nasal dome height, and columella length; horizontal aspects such as nasal base width and nostril width (Figure 2).^{9,10,11} Following the advancement of the assessment medium, there are more parameters to evaluate nasal asymmetry to further improve the accuracy.^{7,12,13}

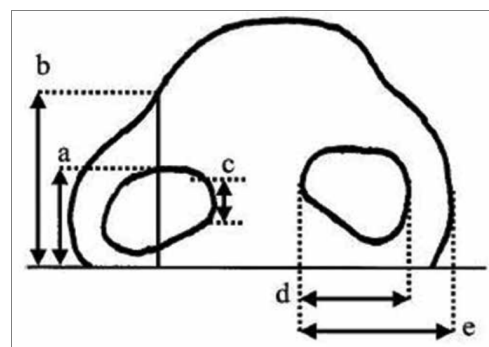


Figure 2. Vertical and Horizontal measurement. a, nostril height; b, nasal dome height; c, columella length; d, nostril width; e, nasal basal width⁹

Table 1. Characteristics of Included Studies

Author (Year)	Country	Study Design	Comparison Group	NA M (n)	Comparison (n)	Assessment Medium	Follow-up
Wolff K.-D., et al. (2020)	Germany	Retrospective cohort	no PSIO	8	8	Photographs	pre-NAM, post-NAM
Thakur S., et al. (2018)	India	Retrospective cohort	-	22	-	Photographs	Initial visit, after cheiloplasty
Kinouchi N., et al. (2018)	Japan	Retrospective cohort	non-NAM	13	16	Photographs	Initial visit, immediately before surgery, after cheiloplasty
Ezzat C.F., et al. (2007)	United states	Prospective cohort	-	12	-	Intraoral casts, extraoral casts	pre-NAM, post-NAM
Bhutiani N., et al. (2020)	India	Prospective clinical trial	-	10	-	Intraoral casts, extraoral casts	pre-NAM, post-NAM, 1-year after surgery
Maliha S.G., et al (2021)	United States	Retrospective cohort	no PSIO	20	21	Photographs	at >14 years old age
Liang Z., et al. (2018)	China	Randomized controlled trial	no PSIO	42	42	Photographs	4-5 years after surgery
Barillas I., et al. (2009)	United States	Cross sectional	no PSIO	15	10	Nasal casts	at 7-11 years old age
Ruíz-Escolano M.G., et al. (2016)	Spain	Prospective cohort	-	20	-	Nasal casts, photographs	Initial visit, before cheiloplasty
Mancini L., et al. (2019)	United States	Retrospective case control	non-cleft	15	10	3-D images	0-4 weeks of age, 1-2 weeks before surgery, 3-5 weeks after surgery
Keçik D., et al. (2009)	Turkey	Prospective cohort	-	22	-	Maxillary casts, nasal casts	Before surgery, after surgery
Gomez D. F., et al. (2012)	United States	Prospective cohort	-	30	-	Nasal casts, photographs	Initial impression, post-NAM
Nayak T., et al. (2020)	India	Retrospective cohort	-	24	-	Photographs	after cheiloplasty, 1-year follow-up, 3-year follow-up, 5-year follow up
Clark S. L., et al. (2011)	United States	Cross sectional	no PSIO	20	5	3-D images	at 2.6-10.0 years old age
Yilmaz R. B. N., et al. (2018)	Turkey	Retrospective cohort	-	42	-	3-D images, nasal casts	pre-NAM, post-NAM
Williams E.	United	Retrospective	no PSIO	28	14	Photographs	Initial visit,

Author (Year)	Country	Study Design	Comparison Group	NA M (n)	Comparison (n)	Assessment Medium	Follow-up
M., et al. (2012)	states	cohort					after surgery
Bangun K., et al. (2021)	Indonesia	Retrospective cohort	no PSIO	6	6	Photographs	1-year post cheilopalatoplasty
Funayama E., et al. (2018)	Japan	Retrospective cohort	no PSIO	10	6	Photographs	initial visit, postsurgery

DISCUSSION

Nasal deformity in patients with UCLP is characterized by displaced lower lateral nasal cartilage, an oblique and short columella, and a depressed dome. The final goal that surgeons want to achieve is an acceptable nasal form after the adolescent growth spurt. Performing radical nasal correction at an early age, such as primary cleft lip repair surgery, increases the difficulty of the following procedure. During the nasal maturation process, interference with normal nasal growth and development may occur. When it happens, touch-up surgery to maintain an acceptable nasal form becomes increasingly difficult due to scarring. It is necessary to maintain nasal form without multiple rhinoplasty, until touch-up surgery after the post adolescent growth spurt. Because of that, less invasive correction during primary cleft lip repair is important and presurgical nasal correction with NAM has become favored.^{3,7,11}

Effectiveness of NAM therapy on nasal symmetry and proportions

Several studies have confirmed the efficacy of NAM on initial surgeries. The use of presurgical infant orthopaedic appliances (PSIO) such as NAM aims to improve facial symmetry before surgery in UCLP patients. A study conducted by Ezzat et al.¹² indicated a remarkable improvement in nasal symmetry and proportions. To accomplish the improvement in the nasal symmetry of the affected nostril, it is necessary to maintain the width of the nasal base. In the Yilmaz et al.⁷ study, NAM therapy can improve nasal symmetry through increasing nasal height and decreasing nasal width of the affected side.

Vertical and horizontal measurements that have been used in several studies showed a

clinically significant lower mean differences in the NAM group compared to the comparison group. These findings suggested that pre-surgical NAM application can improve nasal symmetry and overall aesthetic results.^{10,14,15}

After NAM therapy, preoperative improvement in the columellar angle was achieved.^{14,16} Moreover, primary cheiloplasty can be done easier because NAM diminishes the tension over the soft tissues and reduces severity of deformity in the lower lateral nasal cartilages.⁸ Gomez et al.¹⁴ assessed preoperative improvement in nasal form by a straightening and elongation of columella length on the cleft side, in conjunction with the narrowing of the alveolar segments, lead to improved and favourable nasal symmetry before primary cheiloplasty and nasal repair.

The main problems that have remained after cheiloplasty in patients with UCLP were deficient columella, overhanging nasal apex, and depressed dome.¹⁷ Using NAM before primary cheiloplasty can help the cleft nasal deformity by transforming the depressed alar cartilages, short columella, deviated septum, and widened alar base. Nasal asymmetry in patients with UCLP significantly improved after NAM therapy and was further improved after primary cheiloplasty. Because of that, NAM was a beneficial adjuvant therapy in achieving nasal symmetry in the immediate postoperative period.^{9,16,18}

The slight overcorrection of the alar dome on the cleft direction was suggested as a short-term positive effect of NAM.¹⁹ A retrospective case-control study that was conducted by Mancini et al.²⁰ concluded that primary cheiloplasty after use of NAM in patients with UCLP can produce an average increase of 3.24 mm in nasal tip projection. This may represent a notable overcorrection of nasal tip projection, columella angle, and outer nasal widths when compared to the non-cleft control group. The overcorrection

may be of benefit due to the possibility of impaired growth in patients with UCLP. However, further longitudinal research is required to confirm this hypothesis.²⁰

According to Wolff et al.²¹, NAM therapy was beneficial for patients with severe UCLP. The parameter was increased absolutely in comparison to the non-NAM group with severe UCLP ($P = 0.094$). This parameter reflects, indirectly, the nasal height and inner nostril height-to-width ratio and contributes to the desired nostril shape, which is often disturbed in cases of UCLP. The columella angle experienced the greatest changes in the patients with moderate and severe UCLP that were treated with NAM. These results suggest an advantage for better nasal symmetry.²¹

Nasoalveolar molding works on the principle of plasticity and pliability of cartilage, which is present in the neonates during the initial months after birth. The maternal estrogen levels is higher immediately after birth and reduces within 6 weeks. Transient increments in estrogen levels will subsequently increase neonatal hyaluronic acid and act as a temporary barrier between the intercellular materials, giving the cartilage a temporary lack of elasticity. Because of that, patients with cleft lip and palate should start NAM therapy as early as possible.^{9,15,22,23}

The NAM group in the Bhutiani study¹³ has a greater increase in columella height when the NAM treatment is started earlier. Williams et al.²³ assessed 42 patients with complete UCLP that were divided into two groups. In one group, 28 patients were treated with NAM and in the other group, 14 patients received surgical treatment only. The study reported that there was no difference found of alar groove height symmetry between nasal molding and control subjects. This study outcome may be due to a delay beyond two weeks of life for initiation of nasal molding therapy.²³

Another factor that can contribute to the NAM results is the use of labial taping. The labial taping has the benefit of significantly reducing the alar width of the cleft side resulting in a better nostril formation. Kecik et al.¹⁵ reported that the nostril area and the alar width of the cleft side changed significantly and became nearly symmetrical to the non-cleft side. On the other hand, Gomez et al.¹⁴ reported that the alar base increased slightly. This suggests that labial taping might be required to counteract possible tissue stretching and normal width growth changes.

Long-term effect of NAM therapy on nasal symmetry and proportions

Until touch-up surgery after the post adolescent growth spurt, it is necessary to maintain a favourable nasal form without multiple rhinoplasty. Barillas et al.³ demonstrates that the lower lateral cartilage measurements are more symmetric and nasal septum deviation is significantly reduced in the NAM group patients. Furthermore, the NAM-group demonstrates that the improved nasal symmetry during the time of the primary surgery is maintained for at least 8.75 years.³ Similarly, another study by Ruiz-Escolano et al.⁸ suggests that NAM can reduce severity of deformity in the lower lateral cartilages and the primary cheiloplasty is made easier. Malitha et al.⁵ found that the use of NAM in patients with UCLP during infancy improves nasal symmetry and nasal proportions at the time of nasal maturity compared to patients who are managed without presurgical appliances.

A longitudinal study that was conducted by Nayak et al.¹⁸ found a gradual loss of the mean nasal height, mean gain in nasal width and alar base width, and an increase in the columella deviation from the after cheiloplasty follow-up to the 5-year follow-up as the patients aged. The unequal growth on the cleft and non-cleft sides might be the cause of the loss of symmetry.

Long-term assessment of NAM is necessary to determine its effects on nasal and facial growth as well as patients' self-perception of nasal aesthetics. The patients need to be followed-up till the end of growth and must be evaluated by careful observation at regular intervals for several years for a definite conclusion on the long-term effect of NAM.^{11,23,25}

CONCLUSION

This review consolidates evidence from multiple studies on the effects of NAM on nasal symmetry and proportions in patients with UCLP. Our findings suggest that NAM is a useful adjuvant therapy and produces benefits in achieving nasal symmetry before and after the primary cheiloplasty when compared with no appliance-based presurgical treatment. However, there has not been sufficient evidence yet to conclude the long-term effects of NAM on nasal

and facial growth and it needs to be evaluated further.

Correspondence regarding this article should be addressed to:

Felicia Puspita Sari.
Faculty of Medicine, Universitas Udayana, Bali, Indonesia.
E-Mail: feliciapuspitasari@gmail.com

REFERENCES

1. Impellizzeri A, Giannantoni I, Polimeni A, Barbato E, Galluccio G. Epidemiological Characteristics of Orofacial clefts and its associated congenital anomalies: retrospective study. *BMC Oral Health*. 2019;19:290 DOI: 10.1186/s12903-019-0980-5
2. Watkins SE, Meyer RE, Strauss RP, Aylsworth AS. Classification, Epidemiology, and Genetics of Orofacial Clefts. *Clinics in Plastic Surgery*. 2014; 41(2):149-163. DOI: 10.1016/j.cps.2013.12.003
3. Barillas I, Dec W, Warren SM, Cutting CB, Grayson BH. Nasoalveolar Molding Improves Long-Term Nasal Symmetry in Complete Unilateral Cleft Lip-Cleft Palate Patients. *Plastic Reconstruction Surgery Journal*. 2009; 123(3): 1002-1006. DOI: 10.1097/PRS.0b013e318199f46e
4. Grayson BH, Santiago PE, Brecht LE, Cutting CB. Presurgical Nasoalveolar Molding in Infants with Cleft Lip and Palate. *Cleft Palate-Craniofacial Journal*. 1999;36(6):486-498. DOI: 10.1597/1545-1569_1999_036_0486_pnmiiw_2.3.co_2
5. Malitha SG, Gonchar MN, Staffenberg DA, Grayson BH. The Effects of Nasoalveolar Molding on Nasal Proportions at the Time of Nasal Maturity. *The Cleft Palate-Craniofacial Journal*. 2020;20(10):1-6. DOI: 10.1177/1055665620950139
6. Sischo L, Chan JW, Stein M, Smith C, van Aalst J, Broder HL. Nasoalveolar Molding: Prevalence of Cleft Centers Offering NAM and Who Seeks It. *Cleft Palate-Craniofacial Journal*. 2012; 49(3):270-275. DOI: 10.1597/11-053
7. Yilmaz RBN, Cakan DG. Nasolabial Morphology Following Nasoalveolar Molding in Infants With Unilateral Cleft Lip and Palate. *The Journal of Craniofacial Surgery*. 2018;0(0):1-5. DOI:10.1097/SCS.0000000000004427
8. Ruiz-Escolano MG, Martinez-Plaza A, Fernandez-Valades R, Cortes-Sanchez R, Munoz-Miguelsanz MA, Velasco-Ortega E, Perez-Urena MB, Matar-Satuf K, Espana-Lopez AJ. Nasoalveolar Molding Therapy for the Treatment of Unilateral Cleft Lip and Palate Improves Nasal Symmetry and Maxillary Alveolar Dimensions. *The Journal of Craniofacial Surgery*. 2016;27:1978-1982. DOI: 10.1097/SCS.0000000000003047
9. Thakur S, Singh A, Diwana VK, Rani A, Thakur NS. Dynamic Changes in Nasal Symmetry after Presurgical Nasoalveolar Molding in Infants with Complete Unilateral Cleft Lip and Palate. *African Journal of Paediatric Surgery*. 2020;17:1-4. DOI: 10.4103/ajps.AJPS_5_18
10. Bangun K, Sukasah CL, Kamayana JAS, Basuki A, Halim J, Nahdiyat NUP, Harsanto AN, Pramudita A. Nasal Aesthetic Evaluation Following Pre-Surgical Naso-Alveolar Molding Application: A Single-Blinded Cohort Retrospective Study in Indonesia. *Jurnal Plastik Rekonstruksi*. 2021;8(1):39-47. DOI: 10.14228/jprjournal.v8i1.320
11. Funayama E, Yamamoto Y, Oyama A, Furukawa H, Murao N, Hayashi T, Maeda T, Osawa M. Comparison of Nasal Symmetry Between Presurgical Nasal Stenting and Postsurgical Nasal Retainer Placement in Unilateral Clefts. *The Journal of Craniofacial Surgery*. 2019;30(1): 133-136. DOI: 10.1097/SCS.0000000000004959
12. Ezzat CF, Chavarria C, Teichgraeber JF, Chen J-W, Stratmann RG, Gateno J, Xia JJ. Presurgical Nasoalveolar Molding Therapy for the Treatment of Unilateral Cleft Lip and Palate: A Preliminary Study. *Cleft Palate-Craniofacial Journal*. 2007;44(1): 8-12. DOI: 10.1597/06-009
13. Bhutiani N, Tripathi T, Verma M, Bhandari PS, Rai P. Assessment of Treatment Outcome of Presurgical Nasoalveolar Molding in Patients With Cleft Lip and Palate and Its Postsurgical Stability. *Cleft Palate Craniofac J*. 2020;57(6):700-706. DOI: 10.1177/1055665620906293.
14. Gomez DF, Donohue ST, Figueroa AA, Polley JW. Nasal changes after presurgical nasoalveolar molding (PNAM) in the unilateral cleft lip nose. *Cleft Palate Craniofac J*. 2012;49(6):689-700. DOI: 10.1597/11-007.

15. Keçik D, Enacar A. Effects of nasoalveolar molding therapy on nasal and alveolar morphology in unilateral cleft lip and palate. *J Craniofac Surg.* 2009;20(6):2075-80. DOI: 10.1097/SCS.0b013e3181be88cf.
16. Kinouchi N, Horiuchi S, Yasue A, Kuroda Y, Kawai N, Watanabe K, Izawa T, Hashimoto I, Hassan AH, Tanaka E. Effectiveness of presurgical nasoalveolar molding therapy on unilateral cleft lip nasal deformity. *Saudi Med J.* 2018 Feb;39(2):169-178. DOI: 10.15537/smj.2018.2.21020.
17. Chang CS, Por YC, Liou EJW, Chang CJ, Chen PKT, Noord-hoff MS. Long-term comparison of four techniques for obtaining nasal symmetry in unilateral complete cleft lip patients: A single surgeon's experience. *Plastic and Reconstructive Surgery.* 2010; 126(4):1276-84. DOI: 10.1097/PRS.0b013e3181ec21e4.
18. Nayak T, Parmar R, Bonanthaya K, Shetty P. A Longitudinal Study of The Nasal Symmetry in Unilateral Cleft Lip And Palate Patients Treated With Nasoalveolar Molding. *Indian J Plast Surg.* 2020 Dec;53(3):371-376. DOI: 10.1055/s-0040-1714768.
19. Singh GD, Levy-Bercowski D, Santiago PE. Three-dimensional nasal changes following nasoalveolar molding in patients with unilateral cleft lip and palate: Geometric morphometrics. *The Cleft Palate-Craniofacial Journal.* 2005; 42(4):403-409. doi: 10.1597/04-063.1
20. Mancini L, Gibson TL, Grayson BH, Flores RL, Staffenberg D, Shetye PR. Three-Dimensional Soft Tissue Nasal Changes After Nasoalveolar Molding and Primary Cheilorhinoplasty in Infants With Unilateral Cleft Lip and Palate. *Cleft Palate Craniofac J.* 2019 Jan;56(1):31-38. doi: 10.1177/1055665618771427
21. Wolff KD, Grill FD, Ritschl LM. Comparative Photographic, Retrospective Analysis of Nonsyndromic Cleft Noses Treated with or without NAM. *Plast Reconstr Surg Glob Open.* 2020 Sep 23;8(9):e3045. DOI: 10.1097/GOX.00000000000003045.
22. Liang Z, Yao J, Chen PKT, Zheng C, Yang J. Effect of Presurgical Nasoalveolar Molding on Nasal Symmetry in Unilateral Complete Cleft Lip/Palate Patients after Primary Cheiloplasty without Concomitant Nasal Cartilage Dissection: Early Childhood Evaluation. *Cleft Palate Craniofac J.* 2018 Aug;55(7):935-940. DOI: 10.1597/14-296.
23. Williams EM, Evans CA, Reisberg DJ, BeGole EA. Nasal Outcomes of Presurgical Nasal Molding in Complete Unilateral Cleft Lip and Palate. *International Journal of Dentistry.* 2012:1-5 DOI: 10.1155/2012/643896
24. Clark SL, Teichgraber JF, Fleshman RG, Shaw JD, Chavarria C, Kau CH, Gateno J, Xia JJ. Long-term treatment outcome of presurgical nasoalveolar molding in patients with unilateral cleft lip and palate. *J Craniofac Surg.* 2011 Jan;22(1):333-6. doi: 10.1097/SCS.0b013e31820