

Case Report

TEAMWORK APPROACH IN MANAGEMENT OF ZYGOMATICOMAXILLARY COMPLEX (ZMC) FRACTURE WITH GLOBE RUPTURE: A CASE REPORT

Nungki R Martina^{1*}, Ester P Andyni Manalu², Adilla Ramadhania², & Bony P Simbolon²

1. Plastic, Reconstructive and Aesthetic Surgeon, Christian University of Indonesia Hospital, Jakarta, Indonesia.
2. General Practitioner, Christian University of Indonesia Hospital, Jakarta, Indonesia.

ABSTRACT

Introduction : Zygomaticomaxillary complex (ZMC) fractures are one of the most common fractures of the facial skeleton. Zygomatic fractures can cause ocular and mandibular functional impairment, along with cosmetic defects. The characteristic clinical signs of zygomatic bone fracture include diplopia, infraorbital nerve paraesthesia, flattening of the cheek, and trismus, whereas maxillary fracture may typically cause flattening of the midface and malocclusion. Therefore, surgical reconstruction is required to restore the function and appearance.

Case Report : A 31-year-old man with ZMC fracture and globe rupture underwent open reduction and internal fixation using plate and orbital mesh. We collaborated with an ophthalmologist who performed enucleation and tarsorrhaphy.

Discussion : The reconstruction improved functional and physical aspects and therefore psychological wellbeing. The main goal of the ZMC fracture treatment is to reconstruct the face in terms of functions and aesthetic. Furthermore, reconstruction of the left orbit (orbital rims and walls) as a secondary objective despite the blind eye, improved his appearance enabling formation of a pocket into which an eye implant was inserted. Satisfying functional and aesthetic outcome was achieved in this patient.

Conclusion: A teamwork approach in surgical reconstruction for this case with ZMC fracture which always has an orbital component, was recommended to obtain an effective and optimal result. Both plastic surgeon and ophthalmologist can elaborate patient needs for facial reconstruction especially orbital region with good result.

Keywords: Zygomaticomaxillary Complex (ZMC) fracture; Globe Rupture; Teamwork; Open Reduction Internal Fixation

Latar Belakang: Fraktur zygomaticomaxillary complex adalah salah satu fraktur tulang wajah yang paling sering terjadi. Fraktur ZMC dapat menyebabkan gangguan fungsi okular dan mandibula, hingga mempengaruhi tampilan wajah. Tanda-tanda klinis fraktur ZMC yaitu, diplopia, parestesia saraf infraorbital, pipi datar, dan trismus, sedangkan fraktur maksila biasanya dapat menyebabkan pendataran wajah bagian tengah dan maloklusi. Oleh karena itu, rekonstruksi diperlukan untuk mengembalikan fungsi dan penampilan.

Laporan Kasus: Laki-laki 31 tahun dengan fraktur zygomaticomaxillary complex (ZMC) dan ruptur bola mata menjalani reduksi terbuka dan fiksasi internal menggunakan plate dan orbital mesh. Kami bekerja sama dengan dokter mata untuk menjalani enukleasi.

Hasil: Rekonstruksi dapat meningkatkan status fungsional dan psikologis pasien. Tujuan utama dari perawatan fraktur zygomaticomaxillary complex adalah untuk merekonstruksi wajah dari segi fungsi dan estetika. Selanjutnya, membentuk fungsi rongga orbita (orbital rim dan dinding orbita) sebagai tujuan sekunder, memperbaiki penampilan dan membentuk kantong untuk pemasangan implan mata. Hasil fungsional dan estetika yang memuaskan dicapai pada pasien ini.

Kesimpulan: Pendekatan kerjasama tim dalam rekonstruksi kasus ini direkomendasikan untuk mendapatkan hasil yang efektif dan optimal. Baik ahli bedah plastik maupun dokter mata dapat menjelaskan kebutuhan pasien untuk rekonstruksi wajah terutama daerah orbita dengan hasil yang baik.

Kata Kunci: Fraktur Zygomaticomaxillary Complex (ZMC), Ruptur Bola Mata, Teamwork, Reduksi Terbuka Fiksasi Internal

Conflicts of Interest Statement:

The author(s) listed in this manuscript declare the absence of any conflict of interest on the subject matter or materials discussed.

Received: 20 07 2021, Revised: 20 01 2022, Accepted: 18 04 2022

Copyright by Martina et al, 2022. | P-ISSN 2089-6492; E-ISSN 2089-9734 | DOI: 10.14228/jprjournal.v9i1.326
Published by Lingkar Studi Bedah Plastik Foundation. This is an open-access article distributed under the terms of the Creative Commons Attribution-Non Commercial-No Derivatives License 4.0 (CCBY-NC-ND), where it is permissible to download and share the work provided it is properly cited. The work cannot be changed in any way or used commercially without permission from the journal. This Article can be viewed at www.jprjournal.com

INTRODUCTION

According to AOCMF, ZMC fracture is a zygoma fracture in which all of the four buttresses are involved which are the frontozygomatic, infraorbital rim, zygomaticomaxillary and zygomatic arch buttresses and in which there is always an orbital component that may involve the lateral wall and orbital floor). Zygomaticomaxillary complex (ZMC) fractures are one of the most common fractures of the facial skeleton. Moreover, ZMC fractures are more common in men than women, and mostly occur in the third decade of life.¹ The incidence and etiology of maxillofacial fractures differs from one country to another worldwide, and even within the same country, there are some differences depending on the prevailing socioeconomic, cultural, and environmental factors. The major etiological factor of maxillofacial injuries in earlier studies was traffic accidents. Zygomatic fractures can cause ocular and mandibular functional impairment, along with cosmetic defects. The characteristic clinical signs of zygomatic bone fracture include diplopia, infraorbital nerve paraesthesia, flattening of the cheek, and trismus, whereas maxillary fracture may typically cause flattening of the midface and malocclusion. The most challenging fractures for the surgeon are these involving orbital floor injuries. The best radiological examination for evaluation of zygoma fractures is Waters view, but the gold standard is CT scan, in which it is possible to obtain more information about the fracture, including assessing orbital soft tissues. There are currently no widely accepted treatment protocols or guidelines and technique used for the surgical management of ZMC fractures. The principal treatment for zygomaticomaxillary complex (ZMC) fracture has been open reduction and internal fixation (ORIF). Reduction of the bones of the ZMC repairs facial projection, orbital volume, and aesthetics.^{2,3}

Facial appearance affects the primary of an individual's personality, and facial change due to injury can cause harmful changes in perceptions of how a patient feels and how one interacts and expresses oneself in society. It is essential that we as plastic surgeons must restore not only the soft-tissue injury but the bony infrastructure to each patient's identity. Plastic surgeons should make the necessary assessments with an

ophthalmologist prior to surgical intervention for a complete ocular workup and appropriate documentation for patients with ZMC.^{1,2}

The objective of this work is to report a clinical case of ZMC fracture, as well as its treatment. Furthermore, a teamwork approach in surgical reconstruction for this case was recommended.

CASE REPORT

A 31-year-old male came to the emergency room at our hospital with a chief complaint of open wound in the left orbit due to the explosion of transformer 30 minutes prior admission. He admitted that he was standing less than 100 meters from the exploded transformer. The patient also complained of pain at the injury site. He had no history of fainting, nausea, and vomiting. He also reported taking no medications and having no known drug allergies or sensitivities. Clinical examination of the left orbital region revealed, there was a laceration $\pm 6 \times 2 \times 1 \text{ cm}^3$ with fatty tissue on the base and active bleeding. The left orbit was tender on palpation and associated with depression of the orbital rims. The patient was suffering from open globe injury and multiple upper and lower eyelid lacerations involving both canaliculi.

Ophthalmology examination found that visual acuity testing showed no light perception and there was exposed front orbital bone, laceration wound of the inferior and superior palpebras, and both the left sclera and eyeball were extruded in the affected left orbit. Then we performed CT Scan and 3-D CT scan, showing a fracture of left zygomaticomaxillary complex. (Figure 1) (Figure 2) (Figure 3)

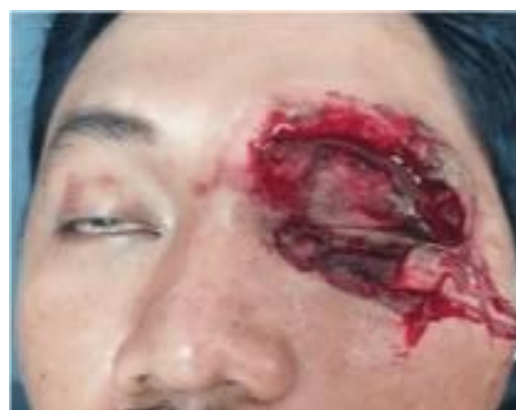

Figure 1. Preoperative physical appearance of the patient

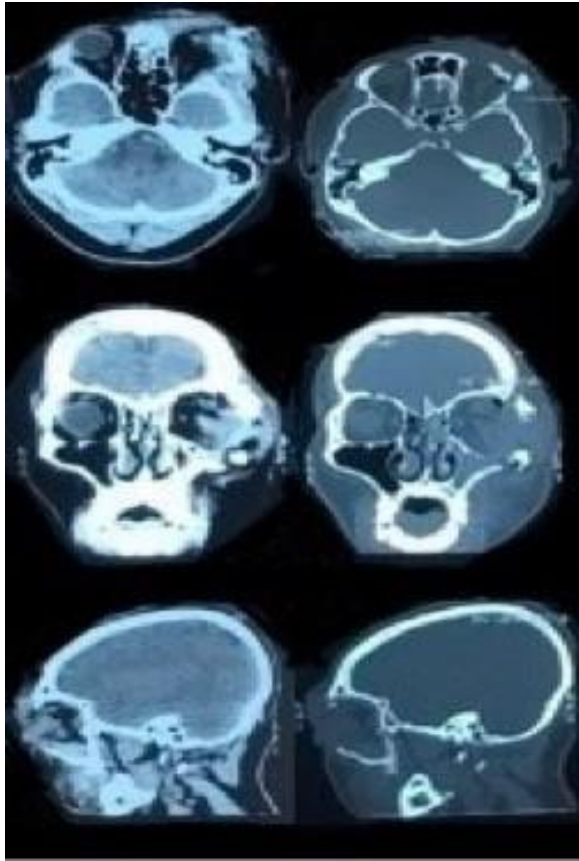


Figure 2. Preoperative facial CT images before reconstruction.

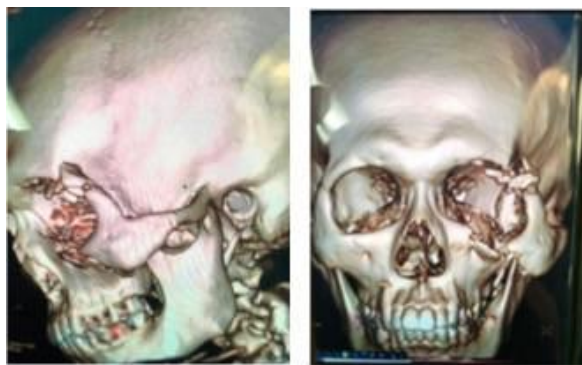

Figure 3. Three-dimensional CT-scan before reconstruction

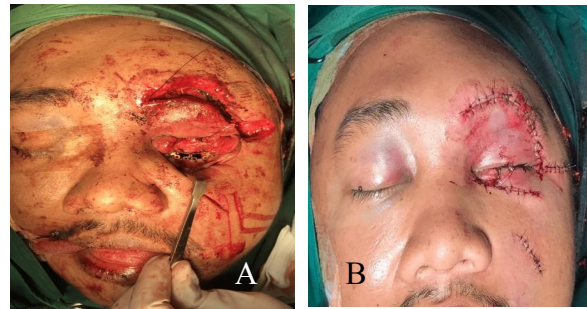

Figure 4. (A) Fixation of fragments during open reduction; (B) Immediate postoperative result

Subsequently, we performed a joint operation with the ophthalmologist. Enucleation was done by the ophthalmologist and ORIF by the plastic surgeon. Intraoperative examination showed an open wound of the left supraorbital, rupture of left orbital contents with exposed bone, and fracture of orbital floor. The surgical approaches for this case are through existing open wound and we explored the fractures then made an incision on the left side of maxilla. Reduction and fixation of the zygomaticomaxillary complex was performed using 1.6 plate system and orbital floor mesh (Figure 3). Three-point fixation of a fracture sites were on the zygomaticomaxillary buttress, the infraorbital rim and front orbital. The wound was sutured in 2 layers using 4.0 Vicryl, 5.0 T.lene for the skin, 4.0 T.vio suture for the left nasolabial fold and 5.0 T.lene for tarsorrhaphy. Postoperatively, the wound healed without infection and with minimal bleeding (Figure 4). Recovery was uneventful with good eye opening and with no cosmetic deficit.

Medication included intravenous antibiotics, analgesics, and proton pump inhibitor. Two days post-op, despite a hematoma, the patient's condition was good, and he was discharged from the hospital. After 3 months, the orbital cavity was re-examined by the ophthalmologist and then we repaired the eye socket and inserted bulbar prosthesis. The implant fabricated by an ophthalmologist (Figure 5) (Figure 6).

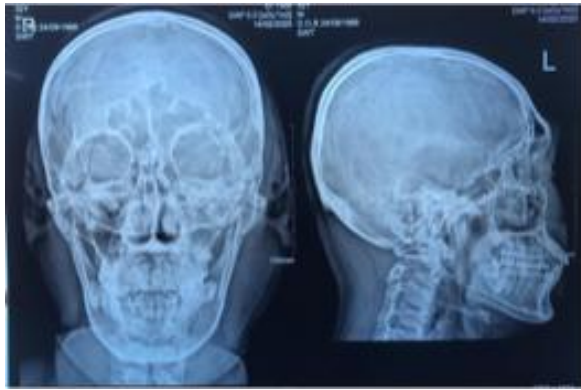


Figure 5. Postoperative X-rays of skull (anteroposterior and lateral views)

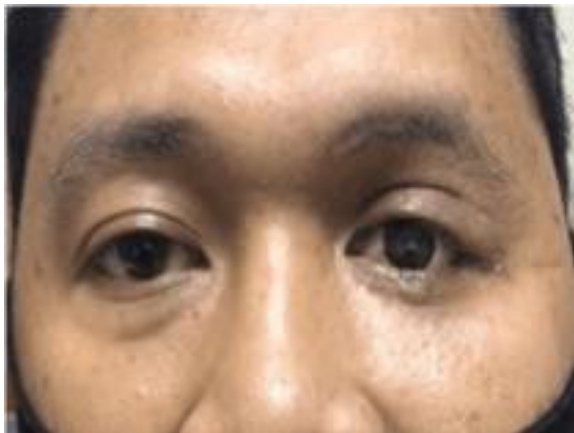

Figure 6. Three months after surgery

DISCUSSION

Zygomaxillary complex (ZMC) fractures are a group of fractures that can significantly alter the structure, function, and aesthetic of the midface, including the eyeball.⁴ Fractures of the zygomaxillary complex are involved in nearly 30% of all facial fractures while orbital fractures are represented in approximately 40% of maxillofacial injuries, making them the most common trauma in the midface. In clinical practice, ZMC fractures are associated with orbital floor fractures, although isolated orbital floor fractures may also occur such as pure blowout fractures.^{3,5} The prevalence of the involvement of orbital floor fractures in ZMC fractures is as much as 46.5%.⁶ According to existing literature, the aetiology is variable, such as road traffic accidents (RTA), assaults, falls, sports, and missile injuries. Balakrishnan et al showed that the highest incidence of ZMC fractures was seen between the age group of 20

and 40 years. Many studies have shown that young adult males were commonly affected. Earlier studies listed traffic accidents as the major etiological factor of ZMC fracture. The plastic surgeon or general practitioner who manage these patients have to understand the related physical findings, including ophthalmologic symptoms and signs. Any misdiagnosis or incorrect reconstruction of the preinjury anatomy can cause post traumatic deformities of the orbit that can lead to complications, including enophthalmos, diplopia, and visual acuity disturbance.^{3,7,8} The frequency of facial trauma is high and can cause many symptoms, depending on the severity and location of the trauma. Changes in the bony orbital dimensions can affect the function of intraorbital contents. On the basis of the anatomic deformities, there are 2 major fracture types resulting in posttraumatic visual dysfunction, blow-out fracture and zygomatic-orbital fractures.^{9,10} Jamal et al found that subconjunctival hemorrhage was the most common minor ocular injury, and found in 55% of ZMC Fracture. Major ocular injuries occurred in 10% of these patients, and included ruptured globe, retinal hemorrhage, and retinal detachment. Ophthalmologic consultation should always be done with, an ocular injury, even with a zygoma fracture. Over the years, CT scan has replaced plain radiography as the imaging modality of choice. In the most complex injuries and those involving multiple planes, three-dimensional CT imaging can be used to help the plastic surgeon better visualize fracture fragments.^{4,11}

The choice of the appropriate treatment is a very important step in the management of facial trauma but this decision is not always easy. ZMC fractures are the most prevalent type of facial fractures and are mostly treated by ORIF. The aims of treatment of ZMC fractures include the restoration of normal facial contour, width and height, normal sensory nerve function, normal globe position, and normal masticatory function.^{12,13} The goal of treating an orbital floor fracture is covering the bony defect and preventing the prolapse of orbital tissues into the maxillary sinus as well as maintaining orbital volume. Furthermore, reconstruction of the orbit (orbital rims and orbital walls) as a secondary objective, improves the appearance and forms a pocket for eye implants to be inserted. This will result in the restoration of function and aesthetics.¹⁴ Ellis and Perez stated that orbital wall reconstruction in ZMC fractures is required

in 44% of cases.¹⁵ Some studies showed that orbital floor exploration and reconstruction was performed in 71% of patients with ZMC fractures as a second surgery because the orbital fractures were not diagnosed before the first surgery.¹⁶ Marinho and Freire-Maia stated that surgical exploration of the orbital floor should be performed when indicated such as in non-resolving oculocardiac reflex, primary diplopia, mechanical entrapment of the extraocular muscles, large defects (greater than 2 cm²), comminution at the infraorbital rim, or CT scan evidence of the need to reconstruct the orbital floor or walls. Therefore, routine orbital floor exploration is unnecessary and should only be performed when indicated.¹⁷

Many patients will have a transient or permanent postoperative infraorbital nerve sensory deficit. The reported incidence of an immediate postoperative sensory deficit approximates 55%, whereas that of a permanent deficit range between 15%-46%. The current literature suggests that the incidence of infraorbital nerve sensory deficits is related to the degree of fracture displacement. The literature further suggests that fracture reduction within the first week after injury will reduce the incidence of a permanent sensory deficit. The most frequent complications described in the literature are infections and opening of soft tissue flaps, mild residual deformity, and complications associated with internal fixation techniques. Generally, after repair of ZMC fractures, the overall results are clinically satisfactory. Postoperative infections are nearly always resolved with oral antibiotics and local wound care. There are many treatment possibilities for ZMC fractures, but the preferred method should be selected individually on the basis of the type of fracture and the patient's characteristic.^{2,4,18}

CONCLUSION

ZMC fractures are a common injury sustained during traumatic incidents. The goal of all surgical procedures in the management of ZMC fracture should be to repair the deficits of function and aesthetics. Each patient with ZMC fracture should be evaluated individually. Multidisciplinary and comprehensive examinations can result in more accurate preliminary recommendations particularly when combined with properly CT-3D scan imaging. A

teamwork approach in surgical reconstruction for this case was recommended to obtain an effective and optimal result. Both plastic surgeon and ophthalmologist can elaborate patient needs for facial reconstruction especially orbital region with good result.

CONSENT

Written informed consent was obtained from the patient for publication of this case report and accompanying images. A copy of the written consent is available for review by the Editor-in-Chief of this journal on request.

Correspondence regarding this article should be addressed to:

Nungki Ratna Martina
Plastic, Reconstructive and Aesthetic Surgeon, Christian
University of Indonesia Hospital, Jakarta, Indonesia 13630
E-Mail: enomartina@gmail.com

ACKNOWLEDGEMENT

We thank to the surgical staff and nursing team who were involved in the patient's care in Faculty of Medicine, Public Health and Nursing, Christian University of Indonesia.

REFERENCES

1. Cornelius CP, et al. The comprehensive AOCMF classification system: midface fractures-level 3 tutorial. *Craniomaxillofacial trauma & reconstruction*. 2014; 7(1): 68-91.
2. Bradley, D. Leung, B. Saxena, S. Dungarwalla, M. Chapiroau, D. Fan, K. Surgical management of zygomatic complex fractures in a major trauma centre. *Plastic and Aesthetic Research*, 6. United Kingdom. 2019:6(11).
3. Wahdini SI. Dachlan I. Seswandhana R. Hutagalung MR. Putri IL. Afand D. Neglected orbitozygomaxillary fractures with complications: A case report. *International journal of surgery case reports*. 2019:62, 35-39.
4. Lee EI, Mohan K, Koshy JC, & Hollier Jr LH. Optimizing the surgical management of zygomaticomaxillary complex fractures. In *Seminars in plastic surgery*. Thieme Medical Publishers. 2010; 24(4): 389.
5. Kanno T, Sukegawa S, Takabatake K, Takahashi Y, & Furuki Y. Orbital floor

- reconstruction in zygomatic-orbital-maxillary fracture with a fractured maxillary sinus wall segment as useful bone graft material. *Journal of Oral and Maxillofacial Surgery, Medicine, and Pathology*. 2013;25(1), 28-31.
6. Bartoli D, Fadda MT, Battisti A, Cassoni A. Retrospective analysis of 301 patients with orbital floor fractures. *J of cranio-maxillo-facial surg*. 2015; 43:244-247.
 7. DS, Y. K., & Bidappa, L. Zygomatico-maxillary complex fractures: A retrospective study on etiology, pattern and management. *Journal of International Medicine and Dentistry*. 2016;3(3):140-150.
 8. Balakrishnan, K., Ebenezer, V., Dakir, A., Kumar, S., & Prakash, D. Management of tripod fractures (zygomaticomaxillary complex) 1 point and 2 point fixations: A 5-year review. *Journal of pharmacy & bioallied sciences*. 2015;7(1): 242.
 9. Kozakiewicz, M., Elgalal, M., Loba, P., Komuński, P., Arkuszewski, P., Broniarczyk-Loba, A., & Stefańczyk, L. Clinical application of 3D pre-bent titanium implants for orbital floor fractures. *Journal of Cranio-Maxillofacial Surgery*. 2009; 37(4):229-234.
 10. Kellman, R. M., & Bersani, T. Delayed and secondary repair of posttraumatic enophthalmos and orbital deformities. *Facial Plastic Surgery Clinics*. 2002;10(3): 311-323.
 11. Jamal, B. T., Pfahler, S. M., Lane, K. A., Bilyk, J. R., Pribitkin, E. A., Diecidue, R. J., & Taub, D. I. Ophthalmic injuries in patients with zygomaticomaxillary complex fractures requiring surgical repair. *Journal of oral and maxillofacial surgery*. 2009;67(5):986-989.
 12. Farber SJ, Nguyen DC, Patel K. Current management of zygomaticomaxillary complex fractures: A multidisciplinary survey and literature review. *craniomaxillofacial trauma reconstruction*. 2016;9:313–322.
 13. Ishida K. Evolution of the surgical approach to the orbitozygomatic fracture: from a subciliary to a transconjunctival and to a novel extended transconjunctival approach without skin incisions. *J plastic, reconstructive & aesthetic sur*. 2016;69: 487-505.
 14. Lima LB, Miranda de Miranda RB, Furtado LM, Rocha FS, De silva MCP, Silva CJ. Reconstruction of orbital floor for treatment of a pure blowout fracture. *Rev port estomatol med dent cir maxilofac*. 2015; 56(2):122–126.
 15. Ellis E, Perez D. An algorithm for the treatment of isolated zygomatico-orbital fractures. *J oral maxillofac surg*. 2014; 72: 1975-83.
 16. Forouzanfar T, Salentjin E, Peng G, Van Den Bergh B. A 10-year analysis of the “Amsterdam” protocol in the treatment of zygomatic complex fractures. *J of cranio-maxillo-facial surg*. 2013; 41:616-622.
 17. Marinho RO, Freire-Maria B. Management of fractures of the zygomaticomaxillary complex. *Oral and maxillofacial surg clin N am*. 2013;25: 617-636.
 18. Bardhoshi, E. Fractures of the zygomaticomaxillary complex and their treatment: A case report. *Balkan Journal of Dental Medicine*. 2016; 20(1),40-43.