

## Reconstructive Rhinoplasty: New Technique of Central Cartilaginous Support

Muhammad Sajid, Zahid Bhatti, Aisha Nazeer, Sadia Mughese, Tayyaba, Mohammad Mughese Amin  
Bahawalpur, Pakistan

**Background:** Honour amputation is a common cause of nose amputation in Pakistan, especially in Bahawalpur region. Skeletal support is always a problem in major nasal amputations. It needs multiple delays and extra support later on, with all traditional techniques.

**Patient and Method:** We reported three cases of amputation of the nose. We used sliding septal technique to reconstruct the central cartilaginous support of the nose. In this technique we used the remaining septum as a free graft. Ten patients were treated with this technique with excellent results. Nasal lining was provided either with septal artery mucosal flap or with nasolabial flap. Forehead flap was the only flap to provide external cover. Nostril rim were grafted with trimmed choncial cartilage primarily. In three patients debulking procedures were done later on, but no skeletal procedures.

**Result:** This technique has given an excellent skeletal support and a nice tip projection with no delays or extra support later on. Patient satisfaction rate was 100%.

**Summary:** Sliding septal technique is a very reliables, cost effective technique. It provides an excellent tip support in a single procedure, without sacrificing other precious material like rib or bone.

**Keywords :** *Rhinoplasty, reconstruction, skeletal support and septum*

**Latar Belakang:** Honour amputation atau hukuman amputasi merupakan penyebab amputasi hidung yang paling sering terjadi di Pakistan, terutama di daerah Bahawalpur. Suport skeletal selalu menjadi masalah utama amputasi nasal. Perlu penundaan dan dukungan ekstra, dengan menggunakan semua teknik tradisional.

**Pasien dan Metode:** Dilaporkan 3 kasus amputasi hidung. Kami menggunakan teknik sliding septal untuk merekonstruksi kartilago sentral yang mensupport hidung. Pada teknik ini kami menggunakan septum yang tersisa sebagai graft. Sepuluh pasien dikerjakan dengan menggunakan teknik ini dengan hasil yang sangat baik. Lapisan hidung dapat menggunakan flap mukosa arteri septal atau flap nasolabial. Flap dahi merupakan satu-satunya flap yang digunakan untuk penutup eksternal. Nostril rim di-graft terutama dengan tulang rawan choncal. Pada tiga pasien debulking dilakukan kemudian tanpa prosedur skeletal.

**Hasil:** Hasilnya, teknik ini memberikan suport skeletal yang sangat baik dan proyeksi tip yang baik tanpa penundaan atau suport ekstra. Tingkat kepuasan pasien adalah 100%.

**Ringkasan:** Teknik sliding septal merupakan teknik yang dapat diandalkan dan efektif dalam hal biaya. Teknik tersebut memberikan hasil tip support yang baik dalam suatu prosedur tunggal, tanpa mengorbankan material berharga seperti rusuk atau tulang.

**Kata Kunci :** *Rhinoplasty, reconstruction, skeletal support and septum*

Received: 17 September 2013, Revised: 10 November 2013, Accepted: 22 November 2013.  
(*Jur.Plast.Rekons. 2013;3:125-130*)

Honour amputation of nose and other body parts is a common problem in Pakistan and the most common cause of nasal amputation. Reconstructing skeletal support is a difficult and challenging problem. It needs to be delayed before reconstructing the final nose with most of the traditional procedures.

Nasal reconstruction constitutes external skin cover, inner lining and midline skeletal support.

Midline skeletal support of Reconstructive nose prevents tip, collapse makes the nose protrude adequately from the face with a naturally high tip.

At first external metallic platforms were fixed with in nasal cavity with a projecting

*From the Division of Plastic Reconstructive and Aesthetic Surgery, Department of Surgery, Faculty of Medicine Universitas Indonesia, Cipto Mangunkusumo Hospital, Jakarta, Indonesia.*

**Disclosure:** *The authors have no financial interest to declare in relation to the content of this article.*



framework shaped as desired.<sup>1</sup> In 1864 Ollier tried autogenous bone grafting.<sup>2</sup> In 1887 a forehead flap with a stent of ulna was used by Israel.<sup>3</sup> Wolkowitsch<sup>4</sup> in 1902 used little finger and in 1908 Mandry used clavicle.<sup>5</sup> Von Mangold in 1900, was the first to describe transplantation of costal cartilage of nasal support.<sup>6</sup> In 1925, Blair's comprehensive review gave the forehead flap priority for nasal cover with local flaps for lining and cartilage for frame work.<sup>7</sup>

Gillies in 1920 introduced the technique of L- strut.<sup>8</sup> It consists of a longitudinal piece of bone or cartilage that is placed on the radix and extended along the dorsum to the tip, where it is bent to rest on the anterior nasal spine. Chait and co-workers prefer a costal osteochondral graft from the fifth rib.<sup>9</sup>

Millard described hinged septal flap in 1973.<sup>10</sup> It is an L-shaped flap of septum hinged superiorly to augment the nasal angle, from the depths of the nose hole. Its limitations are that it does not provide adequate support and later it needs extra support. Secondly, it needs to be delayed.

Septal pivot flap was an expanded version of Sir Gillies concept to bring some skeletal support simultaneously with lining as a composite flap of septum pivoting anteriorly.<sup>11</sup> This flap has got its limitations of delaying the flap, a large perforation in the septum and cases

in which the septal artery is lost due to upper lip amputation this technique cannot be used.

Then Converse and Millard experimented with cantilever bone graft for midline nasal support. The technique consists of a strong, longitudinal piece of bone affixed to the nasal radix that extends along the dorsum down to the tip, and does not need to be further supported up from below.

## PATIENT AND METHOD

### Technique

Sliding septal technique is an easy and effective method to reconstruct the central skeletal support with no septal perforation and the extra cartilage can be used to make the lower lateral cartilages. Normal external nose consists of bony vault, upper lateral cartilages and lower lateral cartilages. In homicidal nasal amputation usually the lower lateral and the upper lateral cartilages are cut but the bony vault is preserved.

The normal septum consists of the quadrangular cartilage, the perpendicular plate of ethmoid and vomer. In nasal amputation, one third to one half of the quadrangular cartilage is lost (Figure 1).

### Procedure

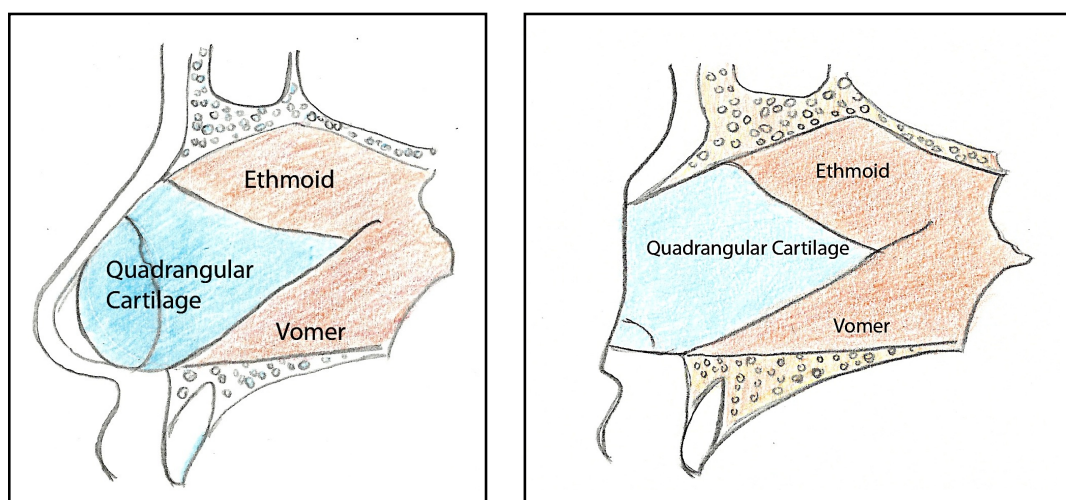
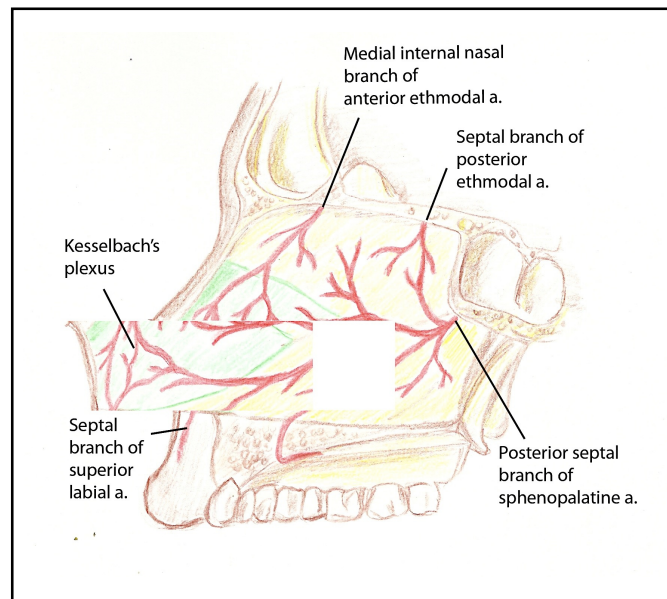


Figure 1. Left : Normal septum Right : Amputated septum

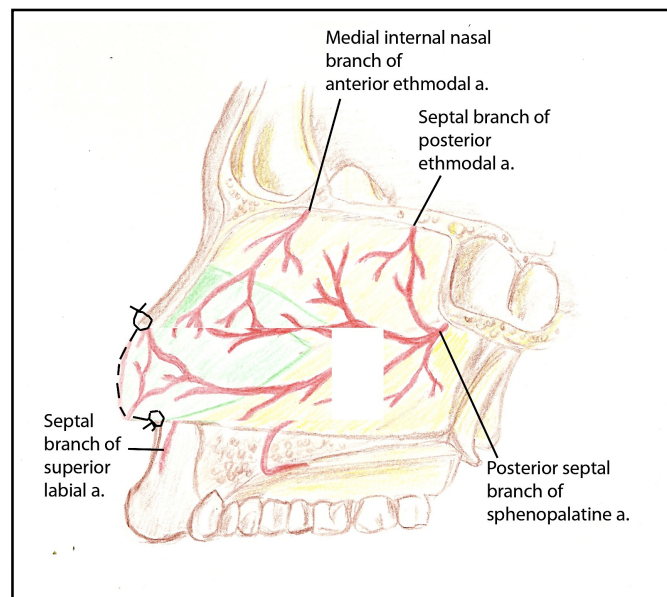
Normal saline with adrenaline was injected in the septal mucosa and ballooned up to separate the mucoperichondrium from the remaining septum. Septum was cut through and through in the shape of a rectangle with an osteotome (figure 2) and sledged forward. When reached to the desired location it was fixed at the anterior nasal spine and dorsum of

the bony vault with prolene or wire sutures. Then excess cartilage was trimmed (Figure 3).

Inner lining of the nose can be made with septal artery flaps only if the septal artery is intact, otherwise bilateral nasolabial flaps or forehead flap have to be used for the lining. Fore head flap is the workhorse for the external skin cover. Alar rims can be fortified with the remnant cartilage from septum.



**Figure 2.** Mucoperichondrial flaps are raised; septum is cut in a rectangle and sledged forward and fixed with anterior nasal spine and dorsal bony vault.



**Figure 3.** Cartilage is trimmed and fixed with the anterior nasal spine and the dorsum of the nose.



### Case 1

A young unmarried lady presented in emergency with subtotal amputation of nose and total upper lip amputation with a sharp instrument. Her nose was reconstructed first with forehead flap for external cover, nasal mucosal flaps for the lining and central support with sliding septal technique. Alar rims were grafted with conchal cartilages. Pedicle of the forehead flaps was divided after 15 days. Upper lip as reconstructed with bilateral full thickness inferiorly based nasolabial flaps and abbe flap. Some lip revision and nose debulking was done a couple of months later (Figure 4). Some lip revision will be done after 3 months. (She married recently)

### Case 2

A middle aged man presented in emergency with subtotal nasal, near total upper lip and bilateral ear amputation. Upper lip was reconstructed with lower lip abbe and bilateral inferiorly based full thickness nasolabial flaps. Nose was reconstructed with forehead flap, sliding septal technique for the central cartilaginous support, and nasolabial flaps for the inner lining. We plan to reconstruct the ears with ribs later (Figure 5). Some nose debulking was done after 3 months.

### Case 3

30 years old male, got his nose amputated by his cousin over a small dispute (Figure 6). Nose reconstruction was done using sliding septal technique with forehead flap.

## DISCUSSION

The normal nose is made up of thin vascular lining, sculptured alar tip cartilages, bone and cartilages braces that buttress the dorsum and side walls and thin external skin.

In normal nose nasal bones and the septum provide dorsal support. Upper lateral cartilages and nasal bones make the lateral wall support.

In honour amputation of the nose, the septum is usually left flushed with the maxilla,

down in the pyriform opening. There must be some way to bring the remaining septum out for the support.

Millard<sup>10</sup> used L-shaped composite chondromucosal flap of full thickness of septum, by basing it above and fixing it on the anterior nasal spine. Then wait for three weeks so that blood supply and fixation is established and the rest of the nose can be constructed later on. It is a three staged nasal reconstruction, plus it leaves a big septal perforation as well. And some time we cannot get the desired nasal tip augmentation and we have to add on to the tip in another procedure. Composite septal pivot flap as described by Burgets, G.C, and Menick, F.J<sup>11</sup> is a versatile and reliable technique in cases where septal artery is preserved. In this part of the world where upper lip is mostly amputated with nose, there is no septal artery (branch of superior labial artery). So the sliding septal technique works wells in these patients. Secondly, composite pivot flap is a multiple stage procedure, where septal sliding technique is a single procedure. Cantilever bone graft and other substitutes like primary rib grafting are difficult options in the first instance with very poor and unreliable results.

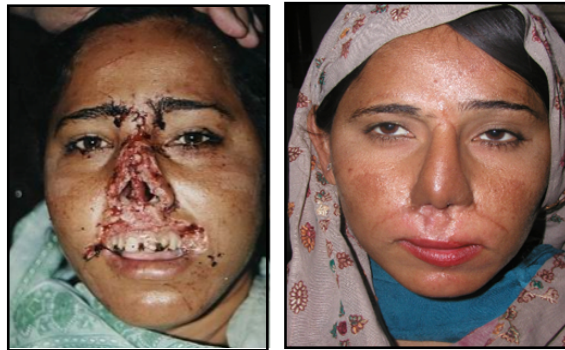## SUMMARY

In this part of the world people are very poor and illiterate. Homicidal honour amputation of the nose is a common phenomenon. Pakistan is poor country and health care system does not provide any free health care facilities. So the patients cannot afford the expenses of multiple stage procedures.

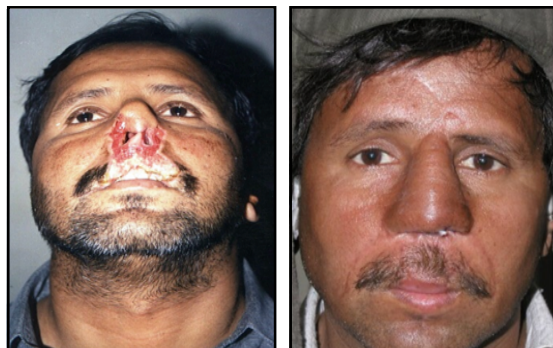Sliding septal technique is a very reliable, cost effective technique. It provides an excellent tip support in a single procedure, without sacrificing other precious material like rib or bone.

### **M. Mughese Amin**

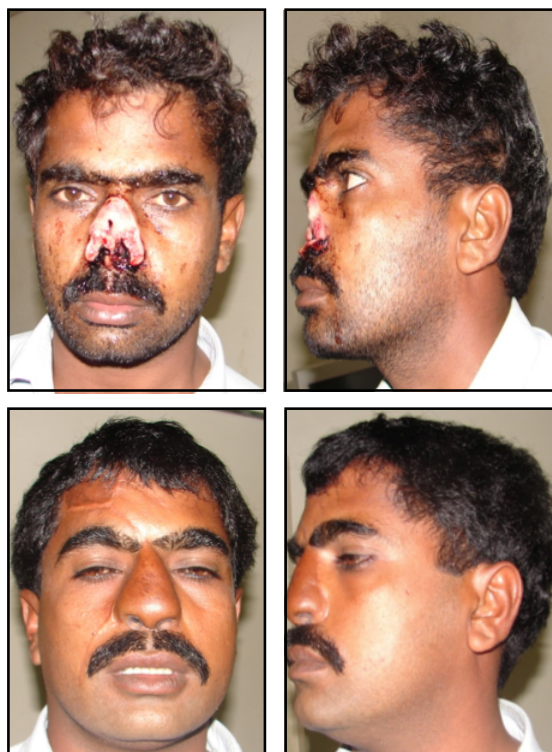*Amin Plastic & Reconstructive Hospital, Bahawalpur, Pakistan and Bahawal Victoria Hospital, Bahawalpur, Pakistan.  
[mughese@yahoo.com](mailto:mughese@yahoo.com)*



**Figure 4.** Case 1. **Left :** Preoperative view. **Right :** Post operative view after a few months.



**Figure 5.** Case 2. **Left :** Preoperative view. **Right :** 3 months after surgery



**Figure 6.** Case 3 **Above :** preoperative **Below :** 3 months post operative views



### REFERENCES

1. Millard DR, Jr. Total reconstructive rhinoplasty and a missing link. *Plast.Reconstr.Surg.* 1966;37: 167-183.
2. Ollier. Des transplants periostiques et osseuses sur l'homme. *Paris*, 1862 nr 22. Osteoplastic appliqué a la restoration du nez. *Soc. Imper de med de Lyon*, 1863.
3. Isrea J. Ubereinige plastischeoperation. *Chior.Kongr.Verhandl.* 1887; 2:85.
4. Wolkowitsch NM. Zum ausfsatze Wredens: Nasenplastik aus dem Finger. *Zentralbl.Chir.s.* 1902;1075.
5. Mandy. Rhinopalstiknit nit director Einpflanzung eines Hautperiosknochenlaapens ausder schlüsselbeinschultergegend. *Beitr.Klin.Chir.* 1908; 77.
6. Von Mangold. Correction of saddle nose by cartilages transplant. *Gesellschr.Chir.* 1900; 29:460.
7. Blair V.P.: Total and subtotal restoration of nose. *JAMA.* 1925; 85:1931.
8. Gillies, H.D. *Plastic surgery of face.* London: Oxford Medical Publishers; 1920.
9. Chait, I.A., Becker, H., Cort, A. The versatile costal osteochondral graft in nasal reconstruction. *Br.J.Plast.Surg.* 1980; 33: 179.
10. Millard DR, JR. Reconstructive rhinoplasty for the lower half of a nose. *Plast Reconstr.Surg.* 1974; 53: 133.
11. Burget GC, Menick FJ. Nasal support and lining: The marriage of beauty and blood supply. *Plast.Reconstr.Surg.* 1989; 84: 189.