

The Efficiency in The Management of Facial Fracture Patients in Developing Country by Using OsiriX®, A Free 3D-Rendering Software

Prasetyanugraheni Kreshanti, Siti Handayani, Kristaninta Bangun
Jakarta, Indonesia.

Background: Being a developing country with a GNI (Gross National Income) per capita of US\$3,830, the cost for managing patients with facial fractures was often unaffordable. The use of a free 3D-rendering software presumably would decrease cost. With OsiriX, a free and open source 3D-rendering software, complex images manipulations and real-time 3D image visualization is easily accessible anytime and anywhere from the surgeon's personal computer, making diagnosis and preoperative planning more convenient for the surgeons.

Patients and methods: From December 2009 to January 2010, 14 patients with facial fracture were admitted to our unit. Seven of them underwent surgery. Preoperatively, diagnosis & surgery plan was developed using OsiriX.

Results: By using OsiriX, more accurate diagnosis was made at a lower cost. Patients could save up to 48.1% from total diagnostic cost (19.2% from monthly income). OsiriX provided easier access to multidimensional navigation and visualization tools in personal computers, making easier planning possible for surgical steps and materials needed.

Summary: OsiriX being free and open source is beneficial from financial point of view, which is an important point for patients in a developing country. It is user friendly and efficient in developing treatment plan for facial fracture patients.

Keywords: *OsiriX, DICOM viewer, 3D, free software, facial fracture, developing country*

Latar Belakang: Menjadi negara berkembang dengan UMR (Upah Minimum Rata-rata) per kapita US \$3,830, biaya untuk manajemen pasien dengan fraktur wajah seringkali tidak terjangkau. penggunaan perangkat lunak *3D-rendering* dimungkinkan dapat memperkecil biaya. Dengan OsiriX, perangkat lunak *3D-rendering* yang bisa didapatkan dan gratis, manipulasi gambar kompleks dan visualisasi foto *3D real-time* mudah diakses kapanpun di manapun dari komputer pribadi dokter bedah, sehingga membuat diagnosis dan rencana operasi lebih baik.

Pasien dan metode: Dari Desember 2009 hingga Januari 2012, 14 pasien dengan fraktur wajah datang ke unit kami. Tujuh diantaranya dilakukan operasi. Sebelum dilakukan operasi, diagnosis dan rencana operasi dilakukan menggunakan OsiriX

Hasil: Dengan menggunakan OsiriX, diagnosis yang lebih akurat dapat dilakukan dengan biaya yang lebih rendah. Pasien dapat menghemat hingga 48.1% dari total biaya diagnosis (19.2% dari upah bulanan). OsiriX menyediakan akses yang lebih mudah untuk navigasi multidimensi dan alat visualisasi di komputer pribadi, membuat rencana operasi dan estimasi bahan yang dibutuhkan lebih mudah.

Ringkasan: OsiriX yang bisa didapatkan dan gratis sangat menguntungkan dari segi ekonomi, di mana merupakan poin penting untuk negara berkembang. OsiriX mudah digunakan dan efisien untuk perencanaan operasi pasien dengan fraktur wajah.

Kata kunci: *OsiriX, DICOM viewer, 3D, free software, facial fracture, developing country*

In our hospital, the incidence of facial fracture was 451 cases from 2001 to 2006, 22.8% was panfacial fracture, mostly due to motorcycle accidents (91.2%) without proper helmet usage (77.8%), involving men (93.2%) of productive age (mean age 26.16 years-old).¹

Being a developing country with a GNI (Gross National Income) per capita of US\$3,830,² the cost for managing patients with facial fractures was often unaffordable. The public medical insurance program has good coverage but the bureaucracy is quite complicated and

From Division of Plastic Reconstructive, and Aesthetic Surgery University of Indonesia Cipto Mangunkusumo Hospital, Jakarta, Indonesia.

Presented in 16th International Congress of the International Confederation for Plastic, Reconstructive, and Aesthetic Surgery (IPRAS), Vancouver, Canada

Disclosure: *The authors have no financial interest to declare in relation to the content of this article.*

sometimes time-consuming. Therefore any expense saving would be beneficial. From financial point of view, the use of a free 3D-rendering software presumably will decrease cost for patients with facial fractures.

In patients with facial fractures, 3D image visualization is helpful in making accurate diagnosis and treatment plan. Facial fractures have been treated by plastic and reconstructive surgeons for many years.³ Advances in imaging techniques (spiral computed tomography, three-dimensional imaging) and associated technologies (i.e. stereolithographic models) have led to improved preoperative planning for the craniomaxillofacial surgeon. Computer-assisted preoperative planning enables the surgeon to predict reconstructive surgical steps before the operation.⁴

OsiriX, a free and open source 3D-rendering software, gives access to referring physicians, surgeons, and other care providers to advanced navigation and visualization tools which were traditionally only accessible on expensive dedicated 3D processing workstations limited to high-end users in a radiology department. Using this software, the referring surgeon may efficiently and conveniently navigate through large sets of multidimensional data, avoiding insufficient data from static snapshots or movie clips inaccurately preselected by the radiologist. With OsiriX, complex images manipulations and real-time 3D image visualization is easily accessible anytime and anywhere from the surgeon's personal computer, making diagnosis and preoperative planning more convenient for the surgeons.⁵

PATIENT AND METHODS

From December 2009 to January 2010, 14 patients with facial fracture were admitted to our unit. Seven of them failed to proceed to operative treatment due to financial difficulties (3 patients), severe coexisting injuries (2 patients), and refusal for further treatment (2 patients). The other seven underwent surgery. Preoperatively, diagnosis & surgery plan was developed using OsiriX. This report will outline 2 cases.

Case 1

A 21 year-old male presented to the ER with history of motorcycle accident, open face helmet was used during the accident. He suffered from panfacial fracture which consisted of bilateral zygomaticomaxillary complex, nasoethmoidal, right superior orbital rim, right frontal, and right parasymphiseal mandible fractures accompanied with dystopia, diplopia, floating maxilla, and malocclusion. The conventional radiograph (skull AP-lateral view photo and Water's view photo) was not performed in the ER, a head CT was performed instead. Using DICOM files from this examination, we generated the 3D image using OsiriX to confirm the diagnosis and develop treatment plan. The patient was planned to undergo an open reduction and internal fixation using plate and screw. The surgery goals were to correct dystopia and diplopia, and to achieve good occlusion. The estimated cost for the internal fixation was calculated accordingly. Intraoperative finding was consistent with the 3D image generated with OsiriX and plating was carried out according to preoperative plan. He spent a total of IDR 19,647,489 (US\$ 2,153) on medical expense. He was covered by public insurance. We had saved IDR 556,000 (US\$ 60.93; 2.83% of the total cost) by not performing conventional radiograph. The surgery was delayed, waiting his insurance paperwork to be completed first. He underwent surgery on the 18th day. There was already a certain degree of ossification as predicted before, making the open reduction more difficult, but the surgery goals were achieved as planned.

Case 2

A 31 year-old male came to the outpatient clinic with history of old bilateral zygomaticomaxillary complex and nasoethmoidal fracture with palatal fracture and palatal defect. He complained of depressed nose, palatal defect and hypernasality, no complaint of malocclusion. We performed a head CT and generated the 3D image using OsiriX. We found ossification

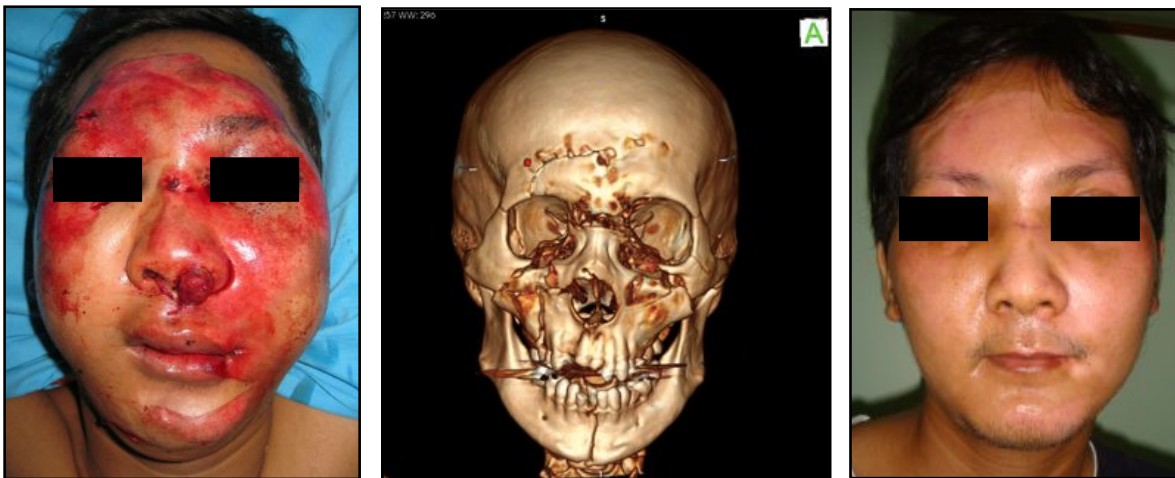



Figure 1. Case 1 with panfacial fracture was performed a 3D image and generated the 3D image using OsiriX to confirm the detailed diagnosis and fracture site to develop treatment plan. **Left.** Pre operative picture. **Middle.** 3D image using OsiriX. **Right.** Post operative picture.

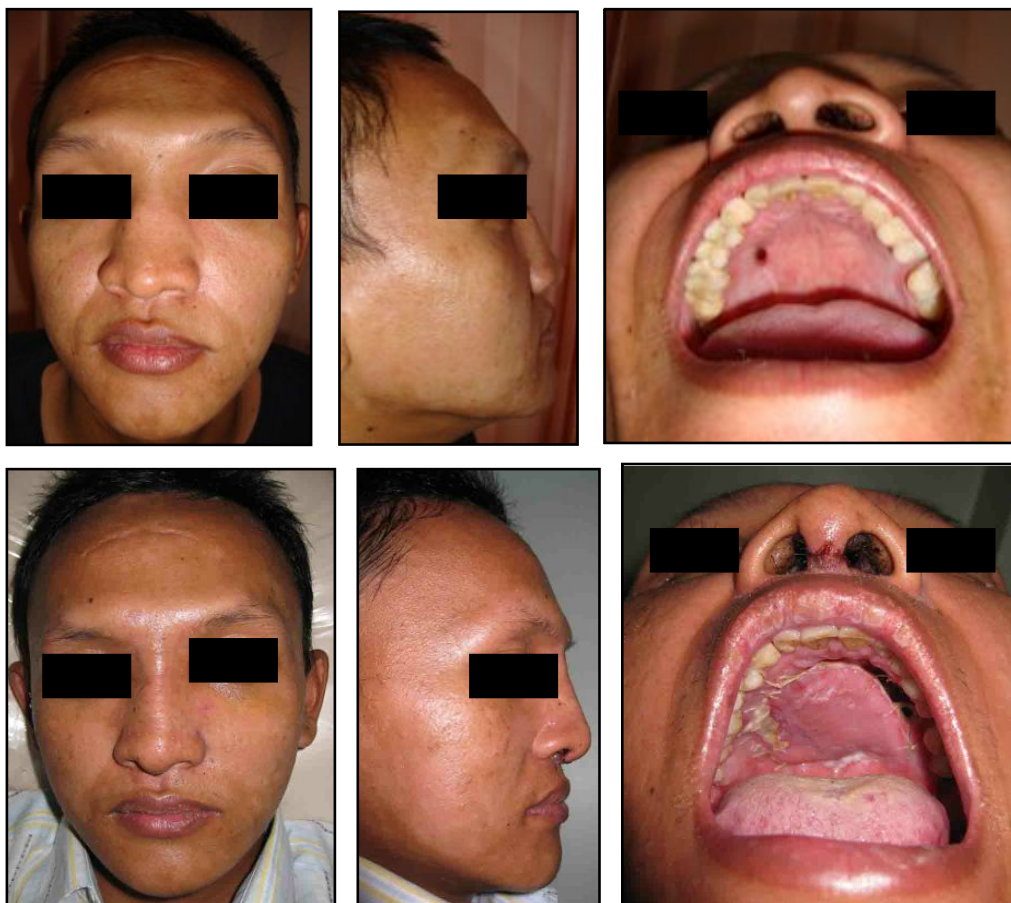

Figure 2. Case 2 with history of old panfacial fracture with depressed nose, palatal defect and hypernasality, was performed a head CT and generated the 3D image using OsiriX to confirm detailed diagnosis and planned treatment. **Above:** Preoperative picture. **Below:** Postoperative picture.

**Table 1.** Patient's profile

No.	Gender	Age (y.o)	MOI	Helmet	GCS on arrival	Surgical intervention
1	Male	21	Motorcycle accident	Y	13	Y
2	Male	29	Train accident	N	15	Y
3	Male	26	Motorcycle accident	N	15	Y
4	Male	21	Motorcycle accident	N	15	Y
5	Male	24	Work accident	N	15	Y
6	Male	26	Motorcycle accident	N	15	Y
7	Male	45	Motorcycle accident	Y	13	Y
8	Male	20	Motorcycle accident	N	11	N
9	Male	20	Motorcycle accident	Y	15	N
10	Male	15	Motorcycle accident	Y	15	N
11	Female	16	Motorcycle accident	N	15	N
12	Male	25	Motorcycle accident	N	11	N
13	Male	49	Motorcycle accident	N	9	N
14	Male	14	Motorcycle accident	N	12	N

GCS=glasgow coma scale; MOI=mechanism of injury; N=no; Y=yes; y.o=years old

Table 2. Summary of cases

No.	Fracture type	LOS (days)	Delay (days)	Cost (IDR, excl IF)	Cost (US\$, excl IF)	Insurance
1	Bilateral ZMC, NOE, right superior orbital rim, right frontal, right parasymphiseal mandible	26	18	19,647,489	2,153	Y
2	Old fracture: LeFort I, NOE, and palatal, with palatal defect	17	13	13,444,684	1,473	Y
3	LeFort II, palatal fracture	17	13	14,035,800	1,538	N
4	Old fracture: bilateral ZMC, NOE, left tripod post ORIF with plate and screw from referring hospital	18	8	16,528,042	1,811	N
5	LeFort III, right tripod	14	8	18,283,051	2,004	Y
6	Bilateral ZMC, NOE, bilateral subcondyle	16	12	21,201,835	2,324	Y
7	Left ZMC, and segmental mandible	11	6	16,858,755	1,848	Y

IDR=Indonesian rupiah; IF=internal fixation and or implants; LOS=length of stay; N=No; NOE=nasoorbitoethmoidal; ORIF=open reduction and internal fixation; US\$=United States Dollar; Y=yes; ZMC=zygomaticomaxillary complex

Table 3. Imaging cost

Item	Cost (IDR)	Cost (US\$)
Skull X-ray (AP & lateral view)	141,000	15.45
Water's view	140,000	15.34
Brain CT (non-contrast)	600,000	65.75
Brain CT 3D print-out	275,000	30.14

IDR=Indonesian rupiah; US\$= United States Dollar

of the fracture lines in an acceptable position. Since there was no malocclusion then we planned not to refracture the fracture site. We correct the appearance of the dorsal nose by placing nasal silicone implant. By manipulating the 3D image with OsiriX we also discovered that there was already some ossification on the palatal fracture site and persistent soft tissue defect. Then we close the palatal defect with local flap. Preoperative, the estimated cost for the material needed in the surgery could be calculated. Intraoperative finding was consistent with the 3D image generated with OsiriX and surgery was carried out as planned. The surgery goals were achieved.

RESULT

From fourteen patients who were treated in our unit, 92.9% were male, with mean age 25.1 years-old, 85.7% due to motorcycle accident, without proper helmet usage in 71.4% of the patients. Mean Glasgow Coma Scale on arrival was 13.5. (Table 1) From the cases observed, the patients were admitted for an average of 17 days. On average, they underwent surgery on the 11.1st day. The total cost they spent during admission was IDR 17,142,808 (US\$ 1,878) on average, not included the materials used during surgery (plate screw or wire or implants). (Table 2) The cost spent on imaging for diagnostic purpose in total was IDR 1,156,000 (US\$ 126.68). (Table 3)

DISCUSSION

The demographic of the facial fracture patients presented in this report was more or less consistent with previous study conducted by Susanto et al in 2009.¹ The facial fractures were mostly due to motorcycle accidents without proper helmet usage and involving men of productive age.

From this report, the average length of stay of facial fracture patients in our hospital was 17 days. The prolonged stay was due to the delay in surgical intervention which was

conducted on the 11.1st day on average. Since the majority of the patients were male of productive age, longer admission time means more working hour loss and less income. And also, the longer their admission time the bigger the total cost they spent, which was IDR 17,142,808 (US\$ 1,878.67) on average, not included the materials used during surgery (plate screw or wire or implants). With GNI (Gross National Income) per capita of only US \$3,830, the medical cost they spent on average was 49.1% of the GNI. Therefore the cost for managing facial fracture patients was often unaffordable by individual. They need insurance coverage.

In our country, the public medical insurance program has good coverage but the bureaucracy is complicated and time-consuming. Most of the delay in surgery presented in this report was resulted from waiting the approval of the insurance coverage. Delay means bigger cost and in the long run it will burden the government. Therefore any measures to decrease cost would help to decrease medical expense that the government has to reimburse. From technical point of view, even though no effect of delay on the probability of infection was identified, postponed surgical intervention may significantly increase the level of difficulty because of osseous callus and soft-tissue fibrosis which leads to a greater risk for technical complications.^{6,7}

Currently, every patient with facial fractures from emergency department in our hospital who requires reconstructive surgery will be admitted and will be scheduled for elective surgery after their insurance coverage is approved. Sanger et al concluded in their research that the cost of the management of isolated facial injuries can be reduced significantly by outpatient management when such treatment is safe for the patient. After evaluating the patient in the ED, they discharged the patient home with strict oral hygiene and a soft diet. They readmitted the patient for repair, optimally within 3 days and not longer than 10 days. They found no increase in complications to the patient by the



delay in treatment while elective surgery time is scheduled.³ Thus, it might be beneficial for us to discharge our patient home and readmit them after their insurance coverage is approved to shorten the length of stay and decrease the medical expense.

In our hospital, the cost spent on imaging for facial fracture patients in total was IDR 1,156,000 (US\$ 126.68). By using OsiriX, we only needed to perform non-contrast CT examination and the DICOM files acquired from this examination could be easily generated to a 3D image which could be manipulated to make more accurate diagnosis compared to conservative radiographic exam. Patients could save up to 48.1% from total diagnostic cost (19.2% from monthly income).

In 2009, Sierra-Martinez et al compared 124 images of patients with facial fractures obtained by the software to the surgical findings. Of the surgical findings, 96.5% matched with the OsiriX images. Only 3.5% of the OsiriX images were not consistent because of distortion or artifacts in the CT due to firearm projectiles and Erich arch bars near the involved area.⁸

OsiriX is a medical imaging program developed by Dr. Osman Ratib (UCLA) and Dr. Antoine Rosset (University of Geneva) in order to display and analyze large radiological data sets on a desktop computer. It is a freeware program available to the public on <http://www.osirix-viewer.com/Downloads.html>. OsiriX is an image processing software dedicated to viewing DICOM (Digital Imaging and COmmunication in Medicine) images produced by imaging equipment (MRI, CT, PET, PET-CT, etc.) and confocal microscopy (LSM and BioRAD-PIC format). It can also read many other file formats: TIFF (8, 16, 32 bits), JPEG, PDF, AVI, MPEG and QuickTime®. OsiriX is released under a free software license and runs under Mac OS X.^{5,9}

Traditionally advanced navigation and visualization tools were only accessible on expensive dedicated 3D picture archiving and communication system (PACS) workstations limited to high-end users in a radiology department. Many times there was loss of

information due to the process of image selection by the radiology staff. OsiriX provides reliable preoperative 3D information for the surgical field which can be obtained at any time. Surgeons are able to perform 3D rendering without extensive training. Thus, reconstructive surgical steps could be planned and also the materials needed could be estimated before the operation.^{4,5,8,10-12}

We installed the application on a laptop (Mac OS X 10.6.1, 2 GB 800 MHz DDR2 SDRAM). By having the application on our personal computer, the surgical team could discuss the surgical steps better anytime anywhere, referring to the 3D images rendered by the application. With this application we reviewed the actual raw image data, not snapshots, and rendered the 3D images to make accurate diagnosis and plan surgical steps preoperatively. And also, the materials needed were estimated and adjusted to patients' insurance coverage or financial capability. Since not all members of the surgical team had a Mac PC, we created a QuickTime® movie with this application to be reviewed in a non Mac PC, so every members of the surgical team could study the images anytime and anywhere. We also referred to the images intraoperatively.

Currently, the application is also available in a very mobile version (iPhone version), making possible to expedite emergency room care when consultation with a craniofacial surgeon is needed. The iPhone interpretations of the CT scans were as accurate as the interpretations viewed on dedicated PACS workstations.¹³ The developer of the application also implemented the software on three other technologies provided on Apple computer platforms which were iPod, iChat, and iDisk. These new technologies developed for communication and storage of data can improve the user convenience and facilitate the communication and transport of images and related data beyond the usual limits and restrictions of a traditional PACS network.¹⁴

With its accuracy in making diagnosis, user friendliness, high mobility, and easiness to share, OsiriX serves as a reliable assistant in

the efficient management of facial fracture patients. By using this software, a more accurate diagnosis could be made, and when a consultation with a craniofacial surgeon is needed, we could easily share the patient's image through mobile phone network. Then we could be more confident to decide on which patient could be sent home safely and wait for elective surgery schedule while completing their paperwork for insurance approval. Thus, the hospital length of stay would be shortened and the overall cost would be decreased. In our institution it would be worthwhile to make a more thorough analysis so that our current policy could be adjusted accordingly.

SUMMARY

Having OsiriX on personal computer, plastic and reconstructive surgeon can access patient's 3D image anytime anywhere to make accurate diagnosis and plan surgical steps preoperatively. OsiriX being free and open source is certainly beneficial from financial point of view, which is an important point for patients in a developing country. It will decrease cost by saving budget for diagnostic. Therefore the management for facial fractures would be more efficient.

Policy adjustment should be considered regarding diagnostic imaging and admission time of facial fracture patients from the ED after a more thorough financial analysis is conducted.

Prasetyanugraheni Kreshanti, M.D.

*Cleft Craniofacial Center. Plastic Surgery Division
Cipto Mangunkusumo General National Hospital
Pras_MD@yahoo.com*

REFERENCES

1. Susanto I, Kesuma AD. Panfacial fracture pattern in Cipto Mangunkusumo National Central Hospital Jakarta: a six year review. Paper presented at: 10th Congress of the International Confederation of Plastic Reconstructive and Aesthetic Surgery/Asia Pacific Section; October 8, 2009; Tokyo, Japan.
2. World Bank. Country classification. In: World Development Indicators Database. Available at: <http://data.worldbank.org/about/country-classifications>. Accessed January 31, 2010.
3. Sanger C, Argenta LC, David LR. Cost-effective management of isolated facial fractures. *J Craniofac Surg* 2004; 15(4): 636-41.
4. Gellrich NC, Schramm A, Hammer B, et al. Computer-assisted secondary reconstruction of unilateral posttraumatic orbital deformity. *Plast Reconstr Surg* 2002; 110(6): 1417-29.
5. Rosset A, Spadola L, Ratib O. OsiriX: An open-source software for navigating in multidimensional DICOM images. *J Digit Imaging* 2004; 17(3): 205-16.
6. Czerwinski M, Parker WL, Correa JA, Williams HB. Effect of treatment delay on mandibular fracture infection rate. *Plast Reconstr Surg* 2008; 122(3): 881-5.
7. Stone IE, Dodson TB, Bays RA. Risk factors for infection following operative treatment of mandibular fractures: a multivariate analysis. *Plast Reconstr Surg* 1993; 91(1): 64-8.
8. Sierra-Martinez E, Cienfuegos-Monroy R, Fernandez-Sobrinho G. [OsiriX, a useful tool for processing tomographic images in patients with facial fracture]. *Cir Cir* 2009; 77(2):95-9.
9. Jalbert F, Paoli JR. [Osirix: free and open-source software for medical imagery]. *Rev Stomatol Chir Maxillofac* 2008; 109(1):53-5.
10. Yamauchi T, Yamazaki M, Okawa A, et al. Efficacy and reliability of highly functional open source DICOM software (OsiriX) in spine surgery. *J Clin Neurosci* 2010 doi:10.1016/j.jocn.2009.09.037.
11. Wang YC, Liu YC, Hsieh TC, Lee ST, Li ML. Aneurysmal subarachnoid hemorrhage diagnosis with computed tomographic angiography and OsiriX. *Acta Neurochir (Wien)*; 152(2):263-9; discussion 269.
12. Melissano G, Bertoglio L, Civelli V, et al. Demonstration of the Adamkiewicz artery by multidetector computed tomography angiography analysed with the open-source software OsiriX. *Eur J Vasc Endovasc Surg* 2009; 37(4):395-400.
13. Choudhri AF, Carr TM, Ho CP, Stone JR, Gay SB, Lambert DL. Handheld device review of abdominal CT for the evaluation of acute appendicitis. Paper presented at: 95th Scientific Assembly and Annual Meeting of Radiological Society of North America; November 30, 2009; Chicago, Ill.
14. Rosset C, Rosset A, Ratib O. General consumer communication tools for improved image management and communication in medicine. *J Digit Imaging* 2005; 18(4):270-9.