

The Effect Of Honey Give As Oral Drops In Precipitating Epithelialization Of Lateral Palatal Defects Post Two-Flap Palatoplasty

Prasetyanugraheni Kreshanti, Gentur Sudjatmiko, Kristaninta Bangun
Jakarta, Indonesia.

Background : Two-flap palatoplasty, which is a very common technique used including in our institution, will result in lateral palatal defects without any periosteal coverage. Faster epithelialization is expected to decrease wound contraction thus reducing scar formation, and in the long run will result in good maxillary growth. In our institution, the retrospective study showed a fair maxillary growth (mean GOSLON score=3.5). Thus, we explore possibilities to precipitate the epithelialization process in pursuit of good maxillary growth in the future.

Method : This is a prospective cohort study conducted in Cipto Mangunkusumo Hospital, on consecutive patients who underwent two-flap palatoplasty from October 2010-February 2011. We followed up these patients weekly for 4 consecutive weeks to observe the rate of epithelialization of the lateral palatal defects.

Result : Two-flap palatoplasty was performed in 48 patients, 23 among them were given honey as oral drops. Eighty-seven point five percent had unilateral complete cleft lip and palate and 12.5% had bilateral complete cleft lip and palate. Faster epithelialization of the lateral palatal defects post two-flap palatoplasty was significantly influenced by intraoral honey application on the wound as oral drops (RR 2.1, 95% CI 1.314 - 3.391, $p < 0.001$).

Conclusion: Honey given as oral drops significantly precipitates the epithelialization process of the lateral palatal defects post two flap palatoplasty 2.1 times faster.

Keywords : *palatoplasty, mucoperiosteal defect, honey, maxillary growth*

Latar Belakang: Two-flap palatoplasty, tehnik yang biasa dikerjakan di institusi kami, menghasilkan defek palatum di bagian lateral tanpa terlapisi periosteum. Untuk mengurangi kontraksi pada luka, diperlukan epitelisasi yang cepat, yang pada akhirnya akan menghasilkan pertumbuhan maxilla yang baik pula. Di institusi kami, sebuah studi retrospektif memperlihatkan hasil berupa pertumbuhan maxilla yang baik (GOSLON score=3.5). Berdasarkan hal tersebut, kami menelaah kemungkinan untuk mempercepat proses epitelisasi tersebut untuk mendapatkan hasil pertumbuhan maxilla yang baik pula.

Metode: Penelitian ini merupakan studi prospektif kohort yang dikerjakan di RSCM, terhadap pasien-pasien yang menjalani prosedur two-flap palatoplasty dari Oktober 2010-Februari 2011. Kami mengikuti pasien-pasien tersebut setiap minggu selama 4 minggu berturut-turut untuk mengobservasi angka epitelisasi pada defek lateral palatum.

Hasil: Two-flap palatoplasty dikerjakan pada 48 pasien, 23 di antaranya diberikan madu sebagai asupan oral. Delapan puluh tujuh koma lima persen memiliki sumbing bibir dan langit unilateral komplit dan 12.5% memiliki sumbing bibir dan langit bilateral komplit. Asupan madu secara oral memiliki hasil yang signifikan dapat mempercepat proses epitelisasi pada defek lateral palatum pasien yang menjalani prosedur two-flap palatoplasty (RR 2.1, 95% CI 1.314 - 3.391, $p < 0.001$).

Kesimpulan: Madu yang diberikan sebagai asupan oral terbukti secara signifikan dapat mempercepat 2.1 kali proses epitelisasi pada defek lateral palatum pasca two flap palatoplasty.

Kata Kunci: *palatoplasty, mucoperiosteal defect, honey, maxillary growth*

Cleft palate is a frequently occurring congenital malformation. Surgical closure of these clefts is indicated to overcome feeding and speech problems. However, the existing surgical procedures lead to scar formation, which impairs the growth of

the maxilla and the development of the dentoalveolar complex.^{1,2,3}

Two-flap palatoplasty, which is a very common technique used including in our institution, will result in lateral palatal defects without any periosteal coverage. These

From Division of Plastic Reconstructive, and Aesthetic Surgery University of Indonesia Cipto Mangunkusumo Hospital, Jakarta, Indonesia.

Presented at the 9th European Craniofacial Congress, Austria

Disclosure: *The authors have no financial interest to declare in relation to the content of this article.*

denuded lateral palatal defects are prone to contamination as palatoplasty is an intra-oral procedure which is a clean contaminated procedure.⁴ Epithelialization of these lateral palatal defects achieved within 3-4 weeks. The wound healing process in these wounds will involve wound contraction, trigger scar formation, and will result in maxillary growth impairment.⁵⁻⁸

Faster epithelialization is expected to decrease wound contraction thus reducing scar formation, and in the long run will result in good maxillary growth.⁹⁻¹² In our institution, the retrospective study showed that the techniques we have been using, which is the two-flap technique, resulted in a fair maxillary growth (mean GOSLON Index score = 3.5)¹³

Thus, we explore possibilities to precipitate the epithelialization process. In this study we explore the effect of honey given as oral drops in precipitating the lateral palatal defects epithelialization.¹⁴⁻¹⁵ As in our previous studies, we found honey to have precipitating effect in epithelialization process by producing a sterile condition in the wound by its antimicrobial action,¹⁶⁻¹⁹ even in a very large defect²⁰ or in patients with severe comorbid conditions (malnutrition, immune-compromised) and severe underlying illness (leukemia).²¹ And as also widely known honey also has effect as a nutritional supplement.^{19,22-4}

Initially, in some of our palate repair patients, we gave honey oral drops as topical antiseptic to reduce contaminations on the lateral palatal defects and in some patients also as a nutritional supplement. It resulted in faster epithelialization of the lateral palatal defects, thus we conducted this prospective study to explore the effect of honey given as oral drops in precipitating epithelialization of the lateral palatal defects post palate repair.

The aim of this study was therefore to evaluate the rate of epithelialization of lateral palatal defects in group of patients who was given honey as oral drops post two-flap palate repair compared to the control group.

METHOD

This study was conducted in One Day Care Operating Theatre, Cipto Mangunkusumo Hospital on cleft palate patients, bilateral or unilateral, who underwent palate repair using two-flap palatoplasty technique (Figure. 1) from October 2010 – February 2011.

Prospective cohort study was performed, with approval of the ethical committee of University of Indonesia, Jakarta. All patients or patient's parents were given informed consent about the study.

Inclusion criteria are unilateral or bilateral cleft palate patients who will undergo palate repair in One Day Care Operating Theatre, Cipto Mangunkusumo Hospital. Exclusion criteria are age less than 1 year-old.^{22,25} Consecutive sampling technique was performed to patients who meet the inclusion and exclusion criteria.

We divided patients into 2 groups. Each group consisted of 24 patients who will undergo two flap palatoplasty technique. The intervention group would be given honey as oral drop in the post operative care, using 1cc pipet 5 times daily, 24 with the patient in sitting position with head extension. Honey would be given until complete epithelialization occurred in the lateral palatal defects. The control group would not be given honey as oral drops in the post operative care. Other standard post operative cares for palate surgery were carried out in both groups.

Honey used in this study is Nusantara® local honey, which is widely available in convenient stores throughout the country with reasonable price. We have performed researches on this honey in our institution and the results revealed anti-inflammatory and antimicrobial effects, autolytic debridement properties, odor reducing effect, ability to maintain moist environment and to precipitate epithelialization.²⁶⁻²⁸

We performed evaluation of lateral palatal defects epithelialization in both control and intervention group. We requested all

patients in each group to have a follow up visit in our hospital every week, for 4 consecutive weeks after surgery, in order to evaluate epithelialization of the lateral palatal defects. We documented all the progress of the epithelialization process.

RESULT

During a 5-month period, we performed two-flap palate repair in 48 patients, twenty-three among them were given honey as oral drops. There are 4 drop-out patients in the intervention group. One of them is due to the child's refusal to take honey because he did not like the taste of honey, the others are due to their residences are outside the province. The median age of the study population was 26 month-old (IQR 18-36) and 60.4% were male. Eighty-seven point five percent had unilateral complete cleft lip and palate and 12.5% had bilateral complete cleft lip and palate.

In univariate analysis (Table 1), we found honey given as oral drops were significantly precipitate lateral palatal defects epithelialization (RR 2.1, 95% CI 1.314 - 3.391, $p < 0.001$). In the intervention group, four patients (21.1%) had complete epithelialization by the time they came back for evaluation 1 week after surgery. Seven patients (36.8%) had complete epithelialization on the second visit (2 weeks after surgery), eight patients (42.1%) had

complete epithelialization on the third visit (3 weeks after surgery). In the control group, all of the patients had not had complete epithelialization by the fourth visit (4 weeks after surgery).

Besides honey, age was also significantly related with faster epithelialization (RR 0.062, 95% CI 0.00 – 0.098, $p < 0.05$).

There are several factors that associated with epithelialization such as age, gender, cleft type and the honey oral drops that has been taken by the patient (Table.1).

In the intervention group we classified their nutritional status into good, over, or underweight using CDC weight for age individual growth charts.²⁹ Sixteen point seven per cent were underweight, 72.2% had good weight for age, and 11.1% were overweight.

We also compared white blood cell (WBC) count before and after surgery in the intervention group. We divided the group into 2 subgroups, which are normal and elevated WBC count. The normal subgroup either had normal WBC count before and after surgery, or the WBC count became normal after surgery. The elevated subgroup had elevated (above normal limits) WBC count after surgery. Fifty eight point three per cent were in the normal subgroup and the other 41.7% were in the elevated subgroup.

DISCUSSION

There are more male (60.4%) than female subjects in this study, and there are more unilateral cleft lip and palate (87.5%). This is consistent with cleft lip and palate prevalence which is higher among male population and the higher incidence of unilateral cleft lip and palate.³⁰⁻³¹

Four patients in the intervention group dropped out. The majority of the drop-out patients resided outside of Jakarta province, and they did not come back for follow-up, most probably because of the long travel distance. This might be a good point to consider when designing a study in the future, to add residences outside of the province as one of the exclusion criteria.

In our study, we divided the epithelialization process to be before 2 weeks

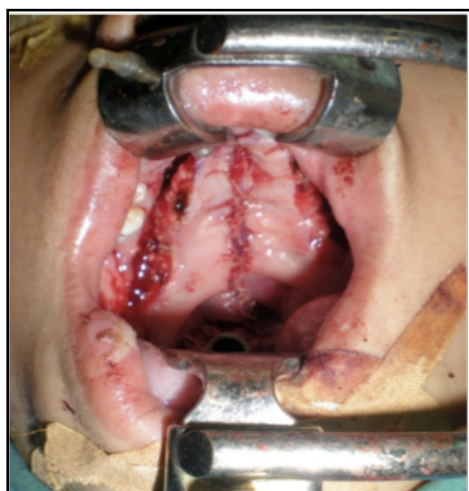

Figure 1. Lateral Palatal Defects Resulted from Two-stage Palatoplasty

Table 1. Factors associated with epithelialization

		Epithelialization	
		< 2 weeks	> 2 weeks
Age		10	34
<i>Mann-Whitney, RR 0.062, 95% CI 0.00 – 0.098, p < 0.05</i>			
Gender	Male	8	20
	Female	2	14
<i>Fisher, RR 2.8, 95% CI 0.515 - 15.225, p 0.2</i>			
Cleft type	Unilateral complete	9	30
	Bilateral complete	1	4
<i>Fisher, RR 1.2, 95% CI 0.119 – 12.143, p 0.683</i>			
Honey oral drops	Yes	10	9
	No	0	25
<i>Fisher, RR 2.1, 95% CI 1.314 – 3.391, p < 0.001</i>			

and after 2 weeks. The proliferative phase lasts 2 weeks in the wound healing process. Complete epithelialization process which occurs less than 2 weeks will have less wound contraction and better scar.^{8-12,32} We identified several factors which might influence the epithelialization process.^{32,33}

We tried to precipitate the epithelialization process by using honey as oral drops. As previous studies showed, honey has the effect in precipitating epithelialization. In this study, honey significantly precipitates the epithelialization process 2.1 times faster (95% CI 1.314 - 3.391).

Experimental studies show that the inflammatory and proliferative phases are less efficient in older animals, particularly compared with very young subjects. Studies suggest that the defect in age-related wound healing is related to abnormal initiation of healing as a result of insufficient presence of growth factors.³² In this study, age was significantly related with faster epithelialization (RR 0.062, 95% CI 0.00 – 0.098, $p < 0.05$).

Malnutrition is well recognized as a risk factor for healing and needs to be recognized and possibly corrected preoperatively. A complete history and physical examination should be performed on each patient. This alone has been found to be 80 to 90 percent accurate in evaluating patient nutritional status, and the addition of multiple or complex biochemical, immune, or anthropometric measurements does not increase greatly the accuracy of nutritional assessment.³³ Honey has

long been known as a nutritional supplement. In this study we tried to evaluate the nutritional status in the intervention group by using CDC weight for age individual growth charts. The majority of the patients (72.2%) had normal weight for age and there is no significant relation with epithelialization process (RR 0.311, CI 0.869 - 1.000; $p 1.0$).

Honey is known to have antimicrobial effect. We tried to see whether that effect is shown in our study by checking WBC count in the intervention group. Although bacterial count is more representative in detecting local infection,³² WBC count has long been used to screen active process of infection. Due to technical limitation in obtaining bacterial count sample from the denuded palate, we decided to perform WBC count to screen whether there is infection process or not. The result was 41.7% did not have elevated white blood cell count after surgery, but it did not affect the epithelialization process significantly (RR 0.5, 95% CI 0.49-5.12; $p 0.5$).


CONCLUSION

In this study, faster epithelialization of the lateral palatal defects post two-flap palate repair was significantly influenced by intra-oral honey application on the wound as oral drops. We plan to have a long term evaluation of our samples to see whether there is a significant relation between the rate of epithelialization and maxillary growth.

Prasetyanugraheni Kreshanti, M.D.
 Cleft Craniofacial Center. Plastic Surgery Division
 Cipto Mangunkusumo General National Hospital
 kristaninta@yahoo.com

REFERENCES

1. Diah E, Lo LJ, Huang CS, Sudjatmiko G, Susanto I and Chen YR. Maxillary growth of adult patients with unoperated cleft: answer to the debates. *J Plast Reconstr Aesth Surg*. 2007; 60: 407-13.
2. Spauwen PHM, Hardjowasito W, Boersma J, Latief BS. Dental cast study of adult patients with untreated unilateral cleft lip or cleft lip and palate in Indonesia compared with surgically treated patients in The Netherlands. *Cleft Palate Craniofac J*. 1993; 30(3): 313-9.
3. Mars M, Houston WJB. A preliminary study of facial growth and morphology in unoperated male unilateral cleft lip and palate subjects over 13 years of age. *Cleft Palate J*. 1990; 27:7-10.
4. National Nosocomial Infections Surveillance (NNIS) System. NNIS report, data summary from October 1986-April 1996, issued May 1996. A report from the NNIS System. *Am J Infect Control*. 1996; 24(5): 380-8.
5. Kremenak CR. Physiological aspects of wound healing: contraction and growth. *Otolaryngol Clin North Am*. 1984; 17: 437-53.
6. Wijdeveld MG, Gruppung EM, Kuijpers-Jagtman AM, Maltha JC. Mucoperiosteal migration after palatal surgery in beagle dogs. A longitudinal radiographic study. *Int J Oral Maxillofac Surg*. 1987; 16: 729-37.
7. Wijdeveld MG, Gruppung EM, Kuijpers-Jagtman AM, Maltha JC. Wound healing of the palatal mucoperiosteum in beagle dogs after surgery at different ages. *J Craniomaxillofac Surg*. 1987; 15: 51-7.
8. Wijdeveld MG, Maltha JC, Gruppung EM, De Jonge J, Kuijpers-Jagtman AM. A histological study of tissue response to simulated cleft palate surgery at different ages in beagle dogs. *Arch Oral Biol*. 1991; 36: 837-43.
9. Greenhalgh DG. The role of apoptosis in wound healing. *Int J Biochem Cell Biol*. 1998; 30: 1019-1030.
10. Huang NF, Zac-Varghese S, Luke S. Apoptosis in skin wound healing. *Wounds*. 2003; 15: 182-94.
11. Desmouliere A, Redard M, Darby I, Gabbiani G. Apoptosis mediates the decrease in cellularity during the transition between granulation tissue and scar. *Am J Pathol*. 1995; 146: 56-66.
12. Clark RA. Wound repair—overview and general considerations. In: *The molecular and cellular biology of wound repair*. Clark RA, editor. 1996. New York: Plenum Press; 1996. p. 3-50.
13. Simamora H, Lamtiur E, Handayani S, et al. Maxillary growth evaluation after cleft palate repair in Cipto Mangunkusumo Hospital using GOSLON yardstick. Paper presented at: 15th Annual Scientific Meeting of Indonesian Association of Plastic Surgeons; May 7, 2010; Semarang, Indonesia.
14. Elbagoury EF, Fayed NA. Application of "natural honey" after surgical removal of impacted lower third molar. *Egyptian Dental Journal*. 1985; 31(3): 203-11.
15. Molan, PC. Potential of honey in the treatment of wounds and burns. *American Journal of Clinical Dermatology*. 2001; 2(1): 13-9.
16. Cooper R. The antibacterial activity of honey. In: White R, Cooper R, Molan P, Eds. *Honey: A modern wound management product*. Wounds UK Publishing, Aberdeen; 2005. 24-32.
17. Subrahmanyam M, Sahapure AG, Nagane NS, Bhagwat VR, Ganu JV. Effects of Topical Application of Honey on Burn Wound Healing. *Annals of Burns and Fire Disasters*. 2001; 14(3): 1-3.
18. Dunford C. The Role of Honey in The Management of Wounds. *Nursing Standard*. 2000; 15(11): 63-8.
19. Jeffry AE, Echazarretta CM. Medical Uses of Honey. *Rev Biomed*. 1996; 7: 43-9.
20. Djoenaedi I, Sudjatmiko G. Topical honey application in treating large ulcerated wound as a complication of vascular malformation in a 5 month-old baby. Paper presented at: 14th Annual Scientific Meeting of Indonesian Association of Plastic Surgeons; May 21, 2010; Balikpapan, Indonesia.
21. Harsono AD, Sudjatmiko G. The effect of honey for granulation tissue of facial bone (mandible bone). Paper presented at: 14th Annual Scientific Meeting of Indonesian Association of Plastic Surgeons; May 21, 2010; Balikpapan, Indonesia.
22. The National Honey Board. *Honey—Health and Therapeutic Qualities*. In press 2004.
23. Wu, C.D., Ashrafi, S.S., Lingstrom, P.K. and Wefel, J.S. Honey and oral/dental health. Grant proposal for the National Honey Board. 2001. University of Illinois at Chicago.
24. Yoirish N. Curative properties of honey and bee venom. Honolulu: University Press of the Pacific; 2001. p. 88, 95.
25. Broughton II G, Janis JE, Attinger CE. A Brief History of Wound Care. *Plast Reconstr Surg*. 2006; 117(Suppl): 6S - 11S.
26. Sundoro A, Sudjatmiko G. Comparison of physical-chemical characteristic and antibacterial effect between medical grade honey and local honey. Paper presented at: 14th Annual Scientific Meeting of Indonesian Association of Plastic Surgeons; May 21, 2010; Balikpapan, Indonesia.
27. Diah A, Sudjatmiko G. Antibacterial activity of local honey against strains of *Pseudomonas aeruginosa*, *Staphylococcus aureus* and Methicillin-resistant *S. aureus*. Paper presented at: 14th Annual Scientific Meeting of Indonesian Association of Plastic Surgeons; May 21, 2010; Balikpapan, Indonesia.
28. Adifitrian T, Sudjatmiko G. Comparison of transparent dressing with honey and conventional transparent dressing on epithelialization rate of split thickness skin graft's donor. Paper presented at: 14th Annual Scientific Meeting of Indonesian Association



- of Plastic Surgeons; May 21, 2010; Balikpapan, Indonesia.
29. National Center for Health Statistics. CDC growth charts. 2000 [cited 2011 17th March]: Available from: <http://www.cdc.gov/growthcharts/data/set2/all.pdf>.
 30. Hopper RA, Cutting C, Grayson B. Cleft lip and palate. In: Thorne CH, Beasley RW, Aston SJ, Bartlett SP, Gurtner GC, Spear SL, editor. *Grabb and Smith's plastic surgery*. Philadelphia: Lippincott Williams & Wilkins; 2007. p. 201.
 31. Salyer KE, Sng KW, Sperry EE. Two-flap palatoplasty: 20-year experience and evolution of surgical technique. *PlastReconstr Surg*. 2006 Jul;118(1):193-204.
 32. Broughton II G, Janis JE, Attinger, CE. Wound healing: an overview. *Plast. Reconstr. Surg*. 2006; 118: 193-204.
 33. Kavalukas SL, Barbul A. Nutrition and wound healing: an update. *PlastReconstr Surg*. 2011 Jan; 127Suppl 1:38S-43S.